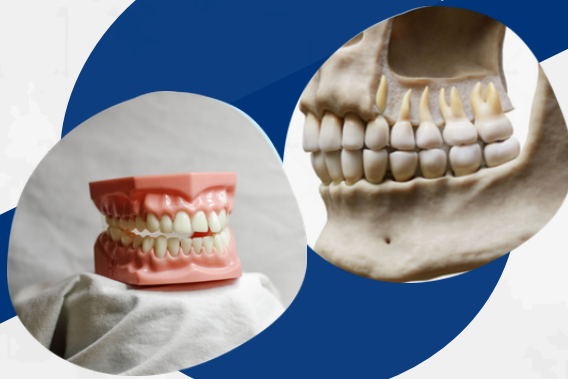

Summary oral science

➤➤➤➤➤ Lecture 3



Writer: Aya Eyad

 Ju_dentistry.com

Anterior teeth (maxillary incisors)

- Teeth that are classified as anterior teeth are:

1. Central incisors
2. lateral incisors
3. canines

- Features of incisors:

1. They are 8 in number (4 maxillary, 4 mandibular)

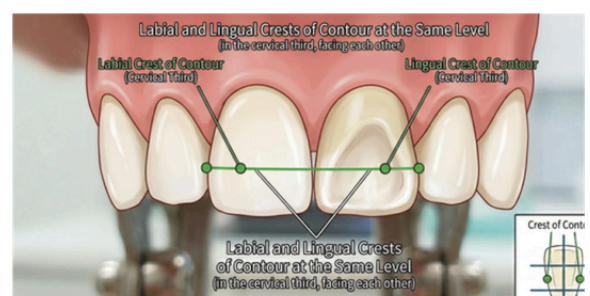
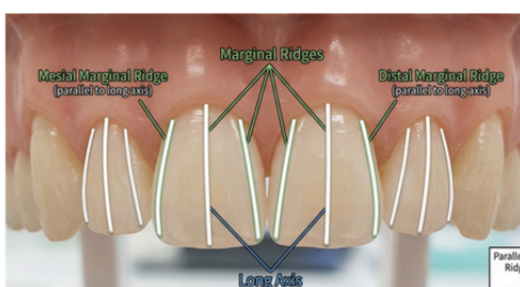
2. classified into: central and lateral incisors

3. Functions:

- Cutting
- Esthetics
- Speech, phonetics

4. Class traits:

- Develop from 4 lobes (3 labial and 1 lingual lobe for cingulum)
- They have single cone shaped tapering roots.
- Labial and lingual aspects: trapezoidal in shape
- Incisal 2/3 flattened MD & compressed LL
- Proximal aspects: triangular
- Incisal portions: Incisal edge/ridge
- Marginal ridges parallel to long axis (see the image below)
- Newly erupted permanent incisors have 3 mamelons (represent the labial lobes)
- Cingulum and lingual fossa
- The contact areas are relatively smaller and are nearly at the same level, especially so in the mandibular incisors
- Their labial surfaces are convex and lingual surface are concavo-convex
- The crests of both labial and lingual contours are at the same level, in the cervical third of the crown, facing each other (see the photo below)
- The cervical lines on their proximal surfaces exhibit greater curvature than on other teeth.



permanent Incisors

Features	Maxillary central	Maxillary lateral	Mandibular central	Mandibular lateral
First evidence of calcification	3-4 months	1 year	3-4 months	3-4 months
Enamel completed	4-5 years	4-5 years	4-5 years	4-5 years
Eruption	7-8 years	8-9 years	7-8 years	7-8 years
Root completed	10 years	11 year	10 years	10 years

Eruption sequence:

Man cen, max cent, man lat, max lat

Measurements:

TABLE 1-1 Measurements of the Teeth: Specifications for Drawing and Carving Teeth of Average Size*

	LENGTH OF CROWN	LENGTH OF ROOT	MESIODISTAL DIAMETER OF CROWN†	MESIODISTAL DIAMETER OF CROWN AT CERVIX	LABIO- OR BUCCOLINGUAL DIAMETER OF CROWN	LABIO- OR BUCCOLINGUAL DIAMETER OF CROWN AT CERVIX	CURVATURE OF CERVICAL LINE—MESIAL	CURVATURE OF CERVICAL LINE—DISTAL
Maxillary Teeth								
Central incisor	10.5	13.0	8.5	7.0	7.0	6.0	3.5	2.5
Lateral incisor	9.0	13.0	6.5	5.0	6.0	5.0	3.0	2.0
Mandibular Teeth								
Central incisor	9.0 [‡]	12.5	5.0	3.5	6.0	5.3	3.0	2.0
Lateral incisor	9.5 [‡]	14.0	5.5	4.0	6.5	5.8	3.0	2.0

Arch traits

Arch trait	Maxillary incisors
Crown	<ul style="list-style-type: none">• Wider Mesiodistally• Smaller height / width proportion• Greater MD / LL proportion• marginal ridges and Cingulum more prominent
Root	<ul style="list-style-type: none">• Root• Greater MD / LL proportion• Conical root in central incisors



Maxillary incisors anatomy

	Central	Lateral
Labial aspect	<ul style="list-style-type: none"> • The widest MD of all incisors • 3 mamelons • 2 labial lobe grooves • 90° mesioincisal line angle. • Rounded distoincisal line angle • Mesial contour straight, distal is rounded and both converge cervically • Mesial height of contour (contact area) within incisal third • Distal HOC at junction between incisal & middle thirds • having a nearly straight incisal edge, a cervical line with even curvature toward the root • Incisal and middle thirds flat • Labial surface less convex than lateral or canine (squared or rectangular appearance) • Incisal edge straight • 2 types: <ol style="list-style-type: none"> 1. converge cervically 2. stay square 	<ul style="list-style-type: none"> • Narrower MD (2mm narrower than the central incisor) - type trait • shorter IC (2-3mm shorter than the central incisor) - type trait • More rounded in general (MI& DI angle and M & D outlines) • HOCs are farther from Incisal edge. • Mesial HOC is between middle & incisal thirds • Distal HOC is at the center of middle third
Lingual aspect	<ul style="list-style-type: none"> • Scoop-like surface • Lingual fossa bordered by Mesial & distal marginal ridges • Cingulum • CEJ more convex than labial& summit toward distal • Root is narrower seen from lingual • Two Developmental grooves from cingulum to fossa • Crown and root converge so lingual side is narrower 	<ul style="list-style-type: none"> • Marked marginal ridges • cingulum prominent • incisal ridge is more developed • lingual fossa is more concave and circumscribed than the central incisor. • It tapers towards the lingual like the central incisor. • Lingual grooves and pits are common

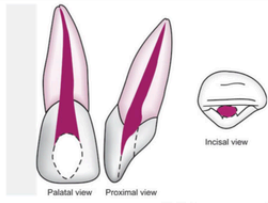
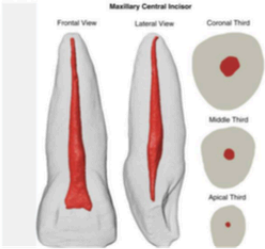
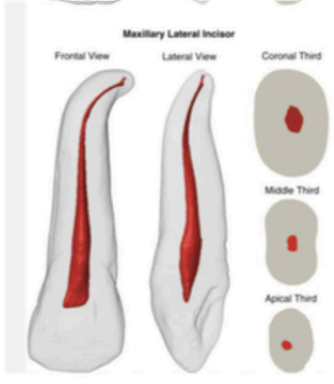
Maxillary incisors anatomy

	Central	Lateral
Mesial aspect	<ul style="list-style-type: none"> • Chisel-shaped • HOC. 5 mm • Labial HOC in the cervical third from HOC to edge convex-straight • Lingually, concave then convex • CEJ curved incisally (the most curved) - type trait • Incisal edge coincides with long axis • Midline bisects apex and edge (arch trait). <p>Rarely the edge is lingual to the line</p>	<ul style="list-style-type: none"> • Cingulum more convex • CEJ less curved • Similar to central except root appears longer, crown is shorter, labio-lingually thinner • incisal ridge thicker well developed • A line drawn through the centre of the root bisects the incisal ridge of the crown.
Distal aspect	<ul style="list-style-type: none"> • Little differences (compared to mesial aspect) • The crown gives an illusion of being somewhat thicker toward the incisal third when viewed from this side due to the slope of the labial surface disto-lingually, more of that surface is seen from the distal aspect. • Most teeth are turned a little on their root bases to adapt to the dental arch curvature. • curvature of the cervical line is less • "most teeth show this characteristic" 	<ul style="list-style-type: none"> • The width of the crown distally appears thicker than mesially from the marginal ridge to the labial aspect due to the placement of the crown on the root. • The curvature of the cervical line • is usually a mm or less than the mesial surface. • A developmental groove may be found on this aspect extending towards the root.

Maxillary incisors anatomy

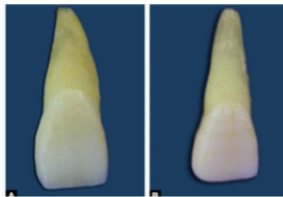
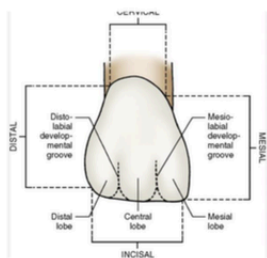
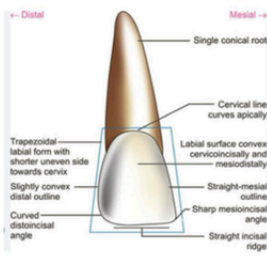
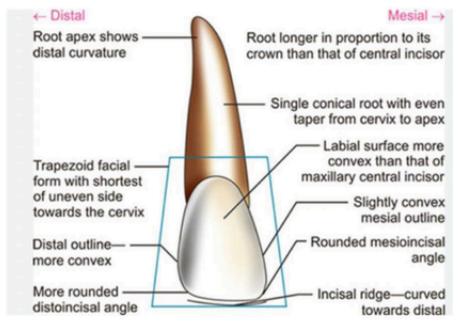
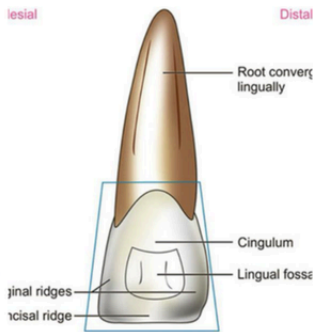
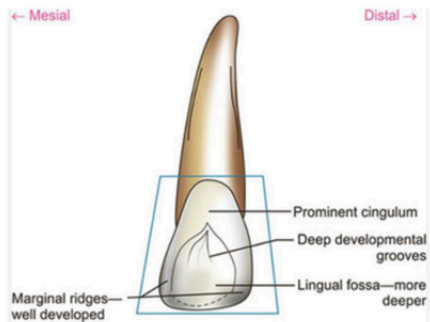
	Central	Lateral
Incisal aspect	<p>Triangular outline</p> <p>Labial outline is slightly</p> <ul style="list-style-type: none"> • convex • Mesial outline is longer than distal • Labial lobe grooves • Edge and apex coincide so • root is not visible • 	<ul style="list-style-type: none"> • Ovoid outline • Smaller MD than central Labial outline is rounded • ML & DL line angles are more rounded • more convexity labially and lingually from this aspect than the central incisor. Sometimes it resembles that of a central incisor and sometimes it looks like a small canine. i.e cingulum may be large as well as the incisal ridge and the labio-lingual width may be greater than usual in comparison with the mesio-distal width.
Root	<ul style="list-style-type: none"> • one and half times as long as the crown. • cone-shaped, tapering gradually from cervical line to apex • Root surface is narrower on lingual aspect. • Cross-section of root at cervix shows triangular shape with rounded border. Base of the triangular is formed by labial aspect and the apex by lingual aspect. • Apex is usually blunt. • Curvature: Root is usually straight without any curvature, if any then distal 	<ul style="list-style-type: none"> • one and a half times the length of the crown • Root length is greater in proportion to the crown length when compared to central incisor. • flat labiolingually • Root tapers evenly from cervical line up to two-thirds of root length • May show developmental groove on mesial and distal surfaces. • Cross-section of root at cervix is oval. • Apical third of root usually shows distal curvature. Sometimes the root ends straight and sometimes curves mesially • Apex is usually pointed

Maxillary incisors anatomy

	Central	Lateral
Variations	<ul style="list-style-type: none"> • Short root • Long crown • Shovel-shaped incisor (prominent marginal ridge seen in Mongoloid races). 	<ul style="list-style-type: none"> • Large size resembling a central • Deep developmental groove (palatoradicular groove) on distal aspect. (interruption groove), predisposing factor to localized periodontal disease. Could happen in central too • Pit in the lingual fossa • Twisted crown or root • Lingual tubercle: large pointed tubercle as part of the cingulum (Tuberculum dentale)
Pulp anatomy	 	
Identification	<ul style="list-style-type: none"> • Tooth with longest crown and single conical, straight root • Crown more symmetrical and wider mesiodistally • Greatest cervical line curvature among all teeth • Lingual fossa and cingulum on lingual aspect • Straight incisal ridge • Sharp mesioincisal angle and rounded distoincisal angle 	<ul style="list-style-type: none"> • Tooth with small asymmetrical crown • Slender and proportionately long root • Round mesioincisal and more rounded distoincisal angle • Rounded incisal ridge • Deep lingual fossa with grooves and pits • Root shows distal curvature at apical 3rd



Maxillary incisors anatomy

	Central	Lateral
Labial aspect	  	
Lingual aspect		

Maxillary incisors anatomy

	Central	Lateral
Mesial aspect		
Distal aspect		
Incisal aspect		

Contact area location:

- Mesial and distal
- labial and lingual

Notes about maxillary lateral incisor:

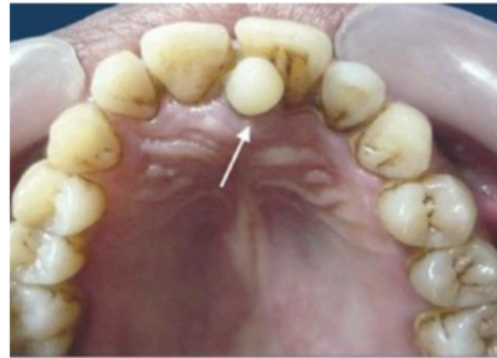- crown resembles the central.
- supplement centrals in function.
- Smaller than the central incisor in all dimensions except the root length.
- vary in form more than any other tooth in the mouth except for the third molar.

Developmental anomalies

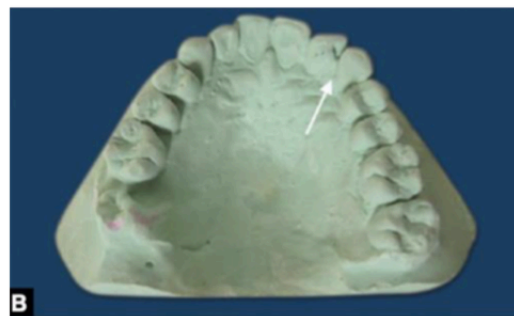
- **Developmental anomalies of maxillary central incisors:**

- **Mesiodens:**

supernumerary tooth between the max central incisors in midline.

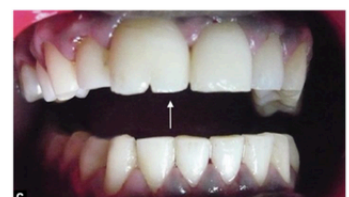
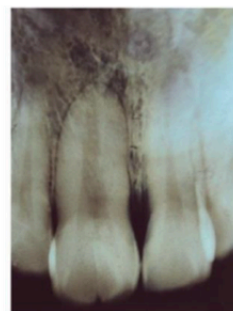
- **Talon's cusp**



- **Gemination**

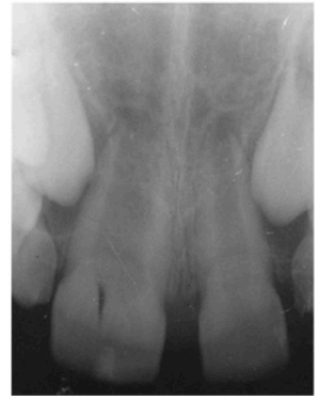gemination occurs when two teeth develop from one single tooth germ and results in a larger tooth crown that radiographically has a single root and single canal



Developmental anomalies

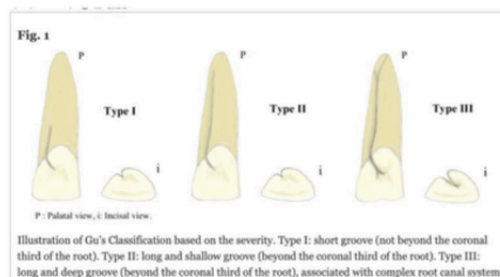
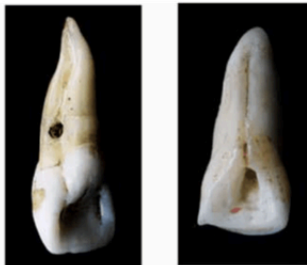- **Fusion**

fusion is a union of two separately developing tooth germs typically leading to one less tooth than normal in the affected arch and radiographically two root canals and two roots



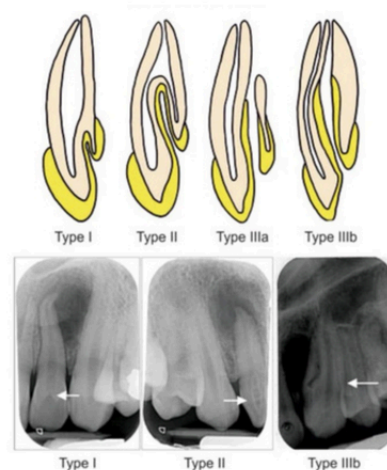
Fusion of a Maxillary Central and Lateral Incisor With a Congenitally Missing Lateral

- **palato radicular groove**



- **Dens invaginatus.**

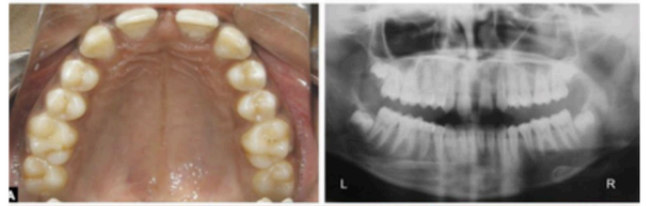
developmental malformation, in which there is an infolding of enamel into dentine. These infolds represent stagnation sites for bacteria and can predispose to dental caries



Developmental anomalies

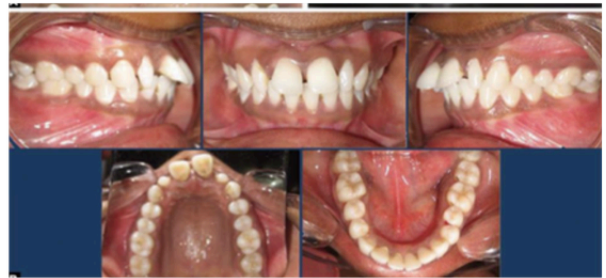- **Developmental anomalies of maxillary lateral incisors:**

- **Congenitally missing laterals**



Most common tooth to be missing next to 3rd molars

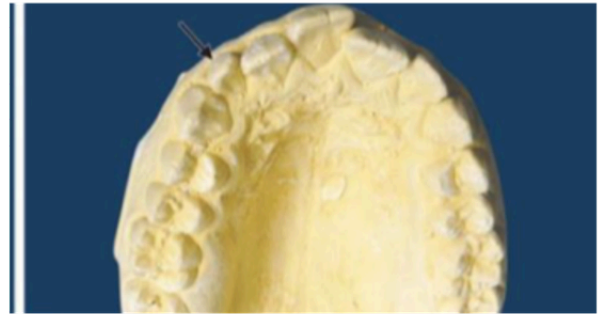- **Peg shaped laterals**
Small conical pointed crown



Developmental anomalies

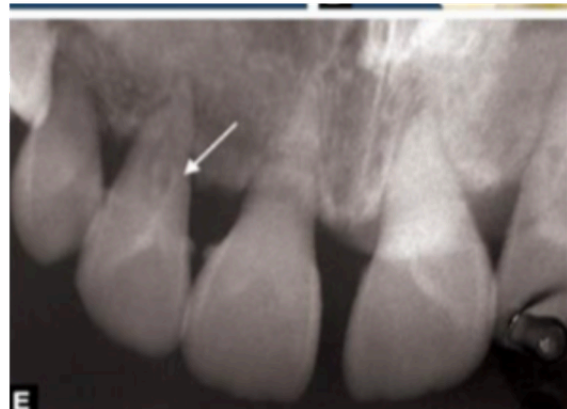- **Developmental anomalies of maxillary lateral incisors:**

- **Supplemental laterals/supernumerary lateral incisor**

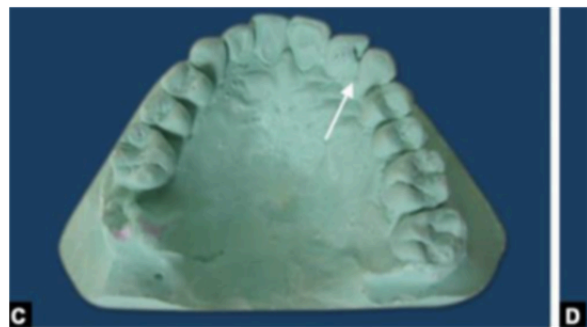


- **Dens invaginatus**

Most common tooth affected.



- **Talon's cusp**



Required resources

Dens Invaginatus

Gemination

- _____ **largest bilateral Gemination**
- _____ **Congenitally missing lateral**
- _____ **palato radicular groove**
- _____
- _____



