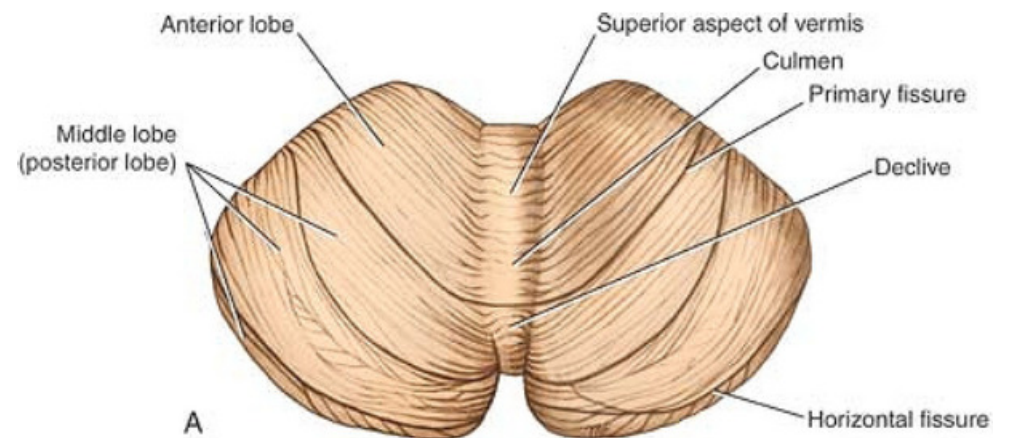
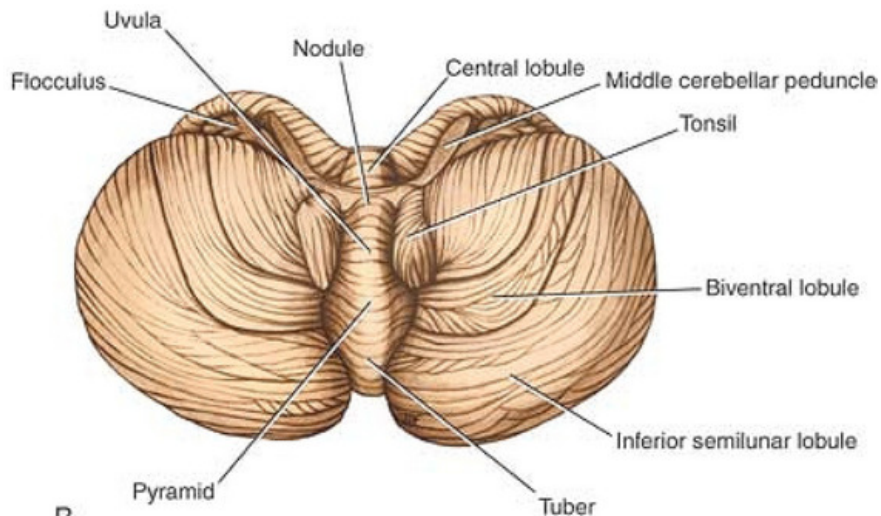
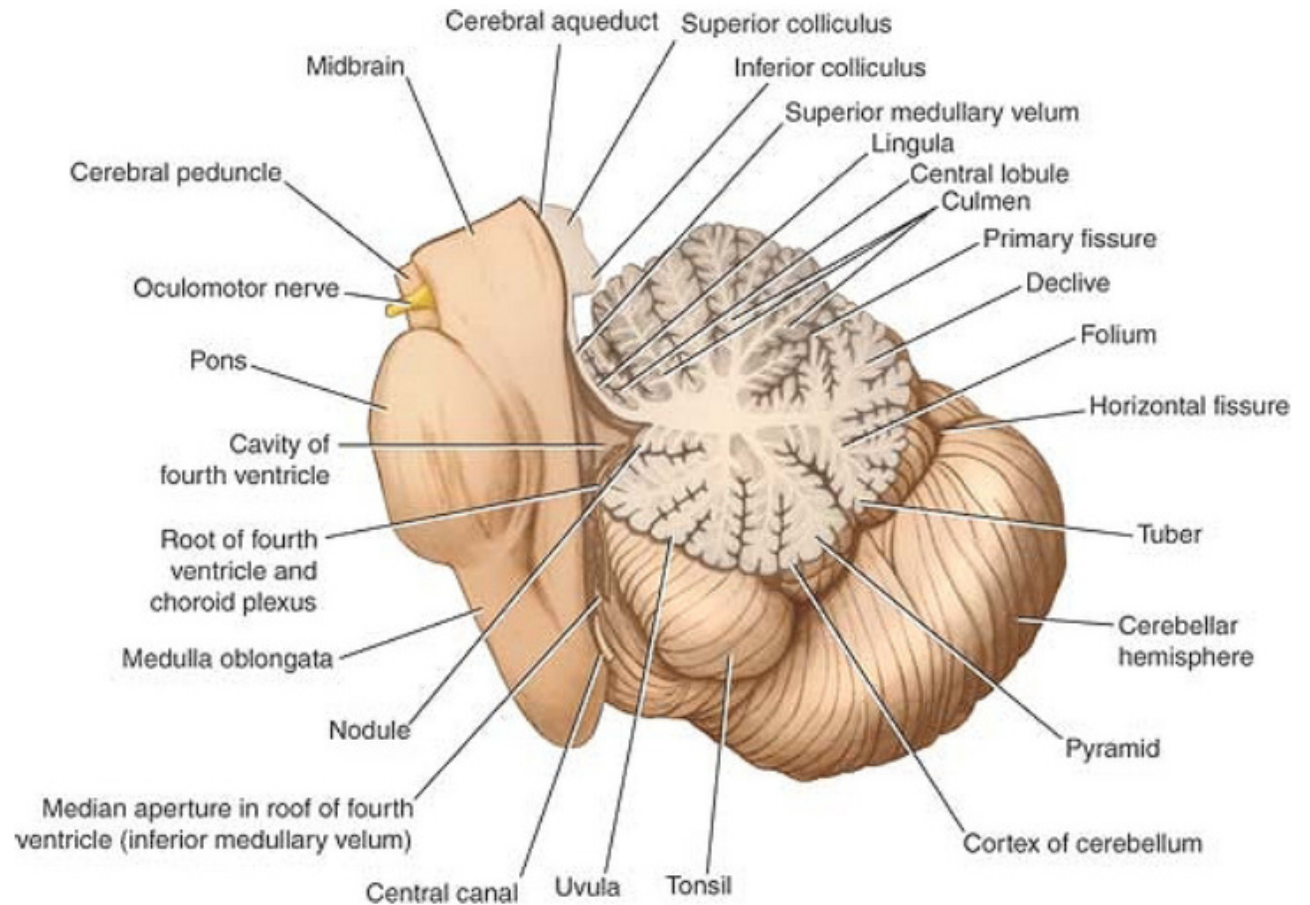


# The Cerebellum

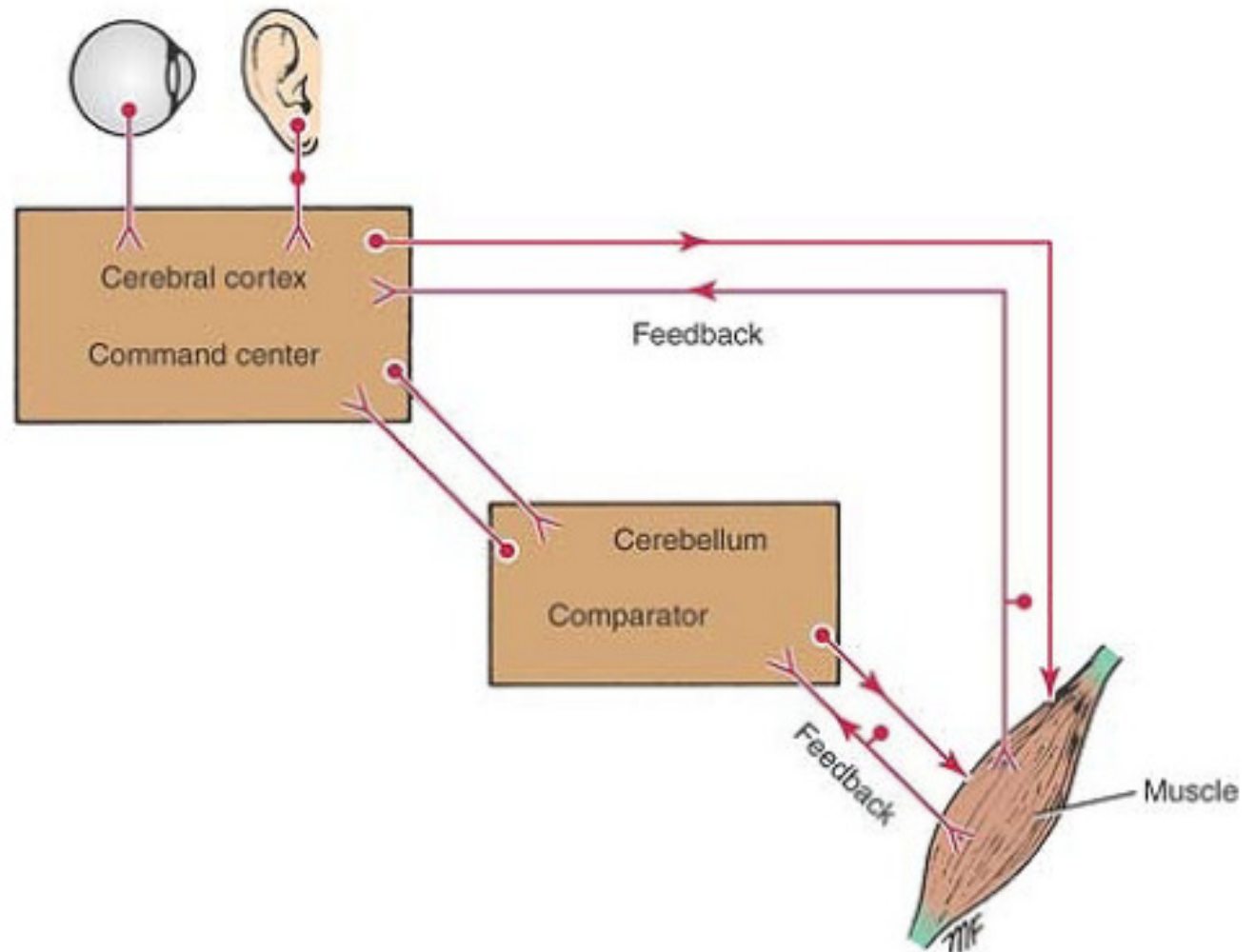
# Cerebellum

- Located below tentorium cerebelli within posterior cranial fossa.
- Formed of 2 hemispheres connected by the vermis in midline.
- Gray matter is external.
- White matter is internal, contain several deep nuclei with the largest is the dentate nucleus.



# Functions of Cerebellum

- Maintenance of posture and balance.
- Maintains muscle tone.
- Coordinates voluntary motor action.



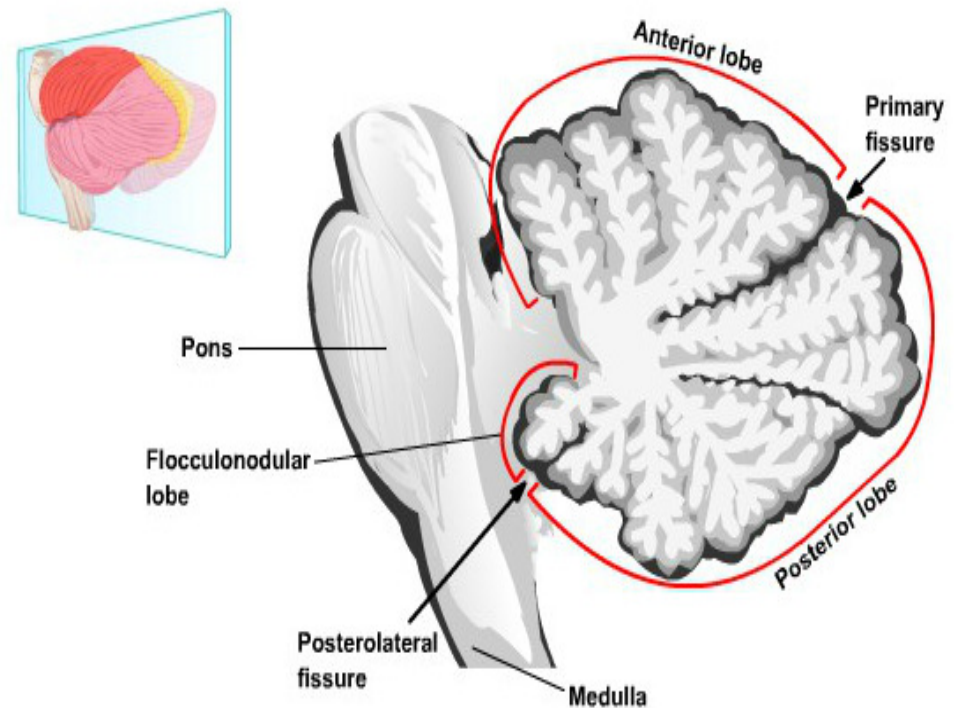
# Cerebellum

## Three lobes

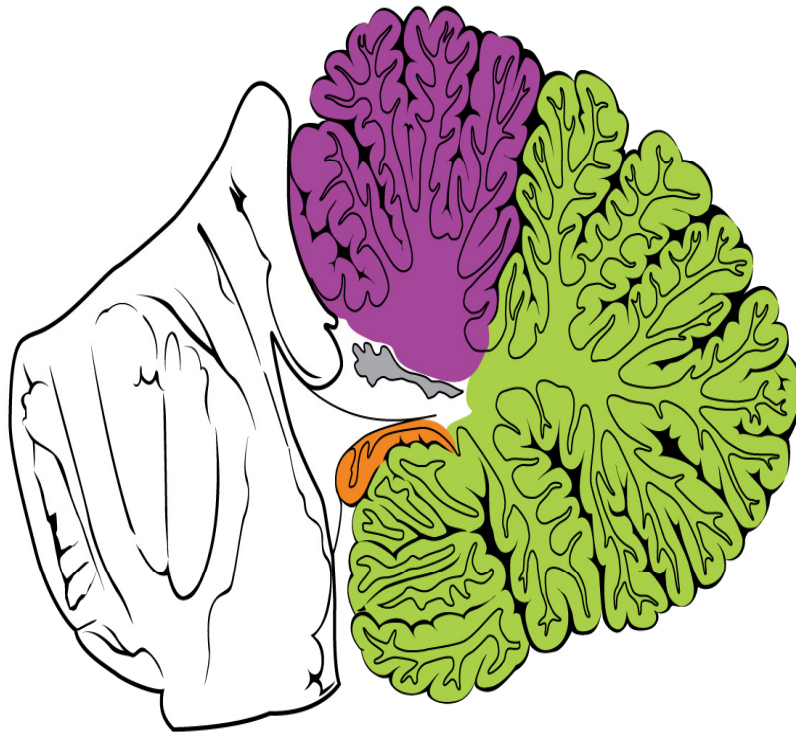
1. Anterior lobe
2. Posterior lobe
3. flocculonodular lobe

## Two main fissures:

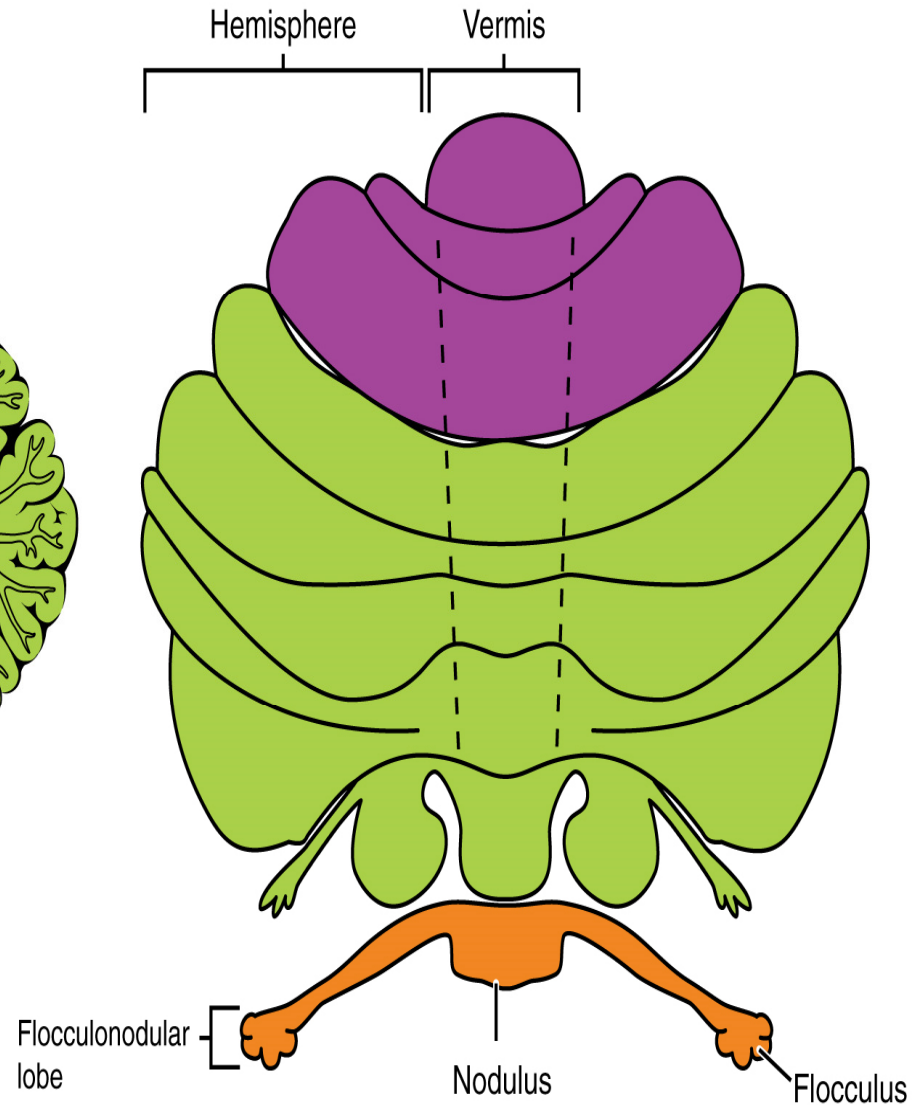
- The **primary fissure** separates the **posterior lobe** from the **anterior lobe**
- The **posterolateral fissure** (**uvulonodular fissures**) separates the **flocculonodular lobe** from the **posterior lobe**



Midsagittal section of cerebellum



Superior view of an "unrolled" cerebellum

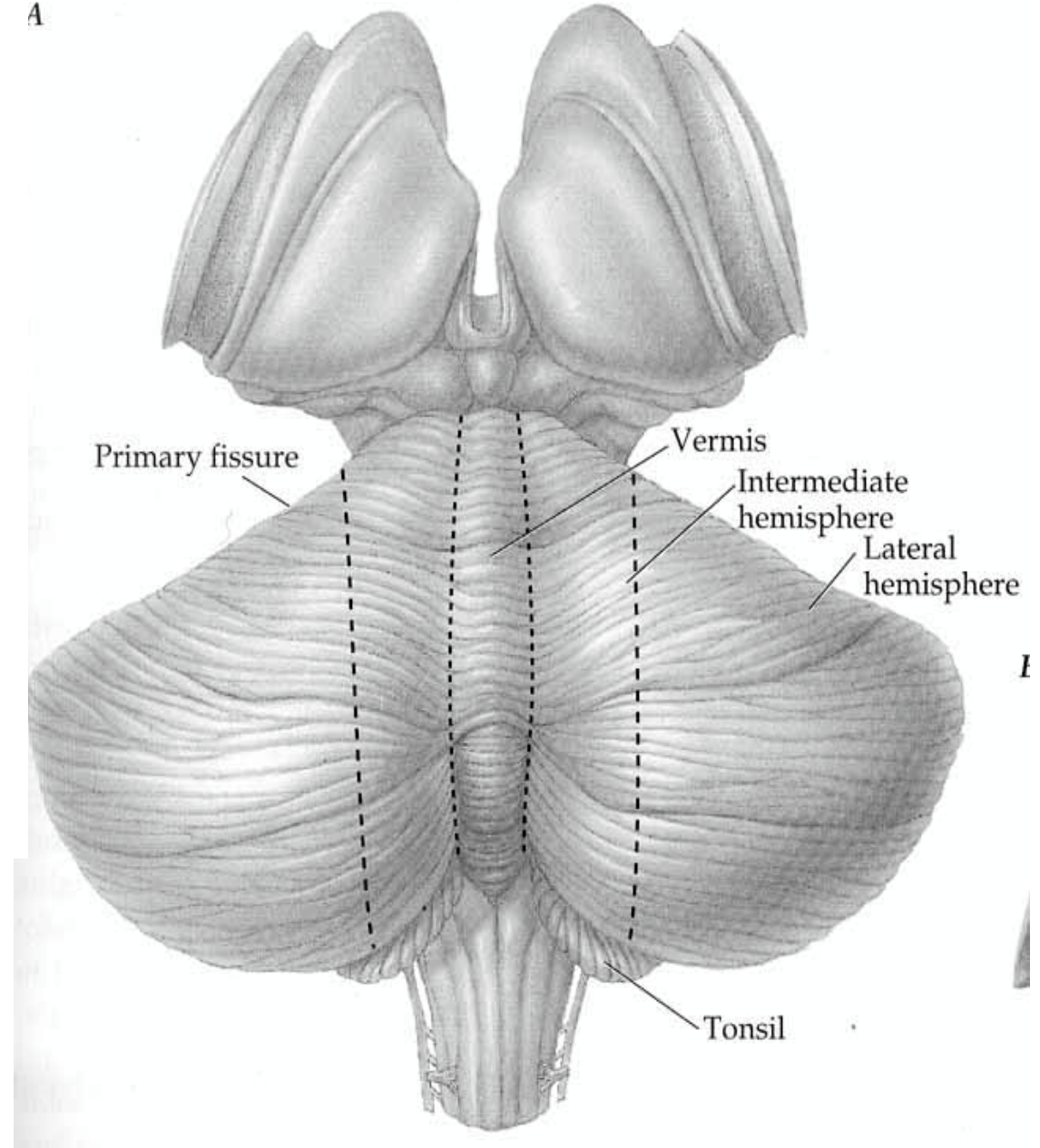


Cortex = organized into groups of folia = 10 lobules and 3 lobes,

Major anatomical divisions (reflecting functional regions)

1. **vermis**
2. **intermediate zone**
3. **lateral hemispheres**

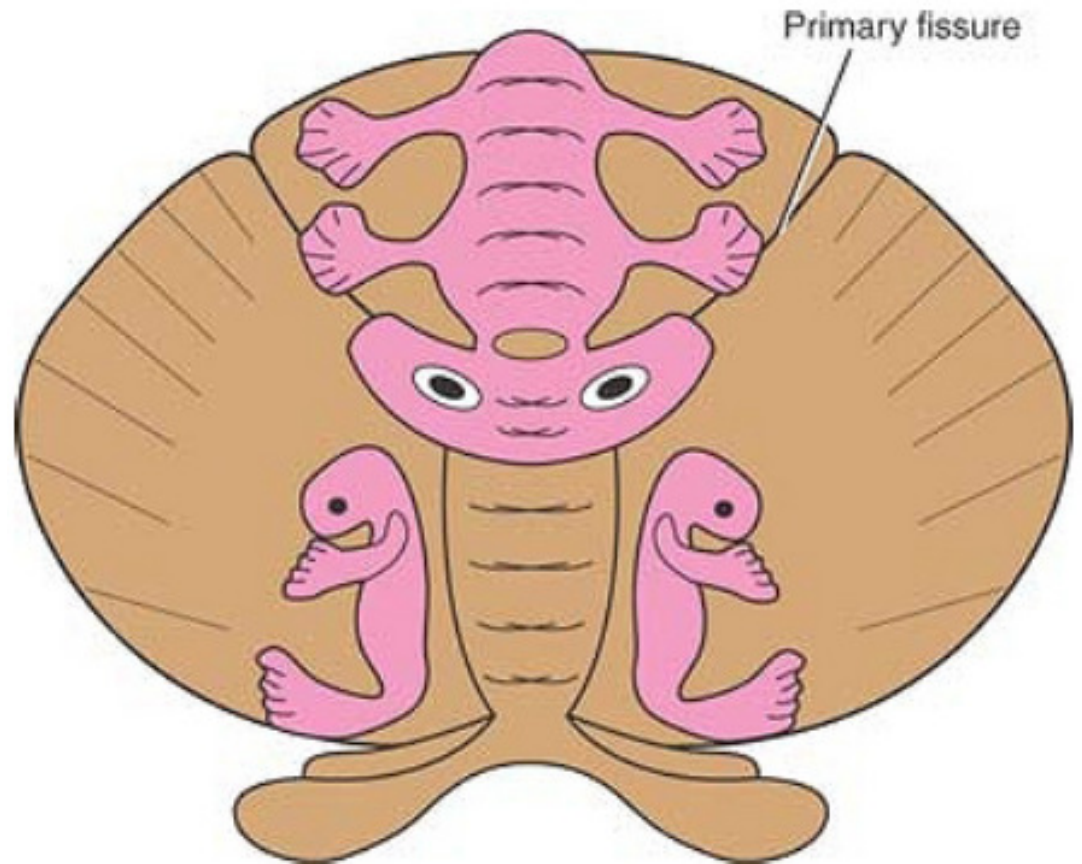
➤ no clear morphological borders between the intermediate zone and the lateral hemisphere that are visible from a gross specimen.



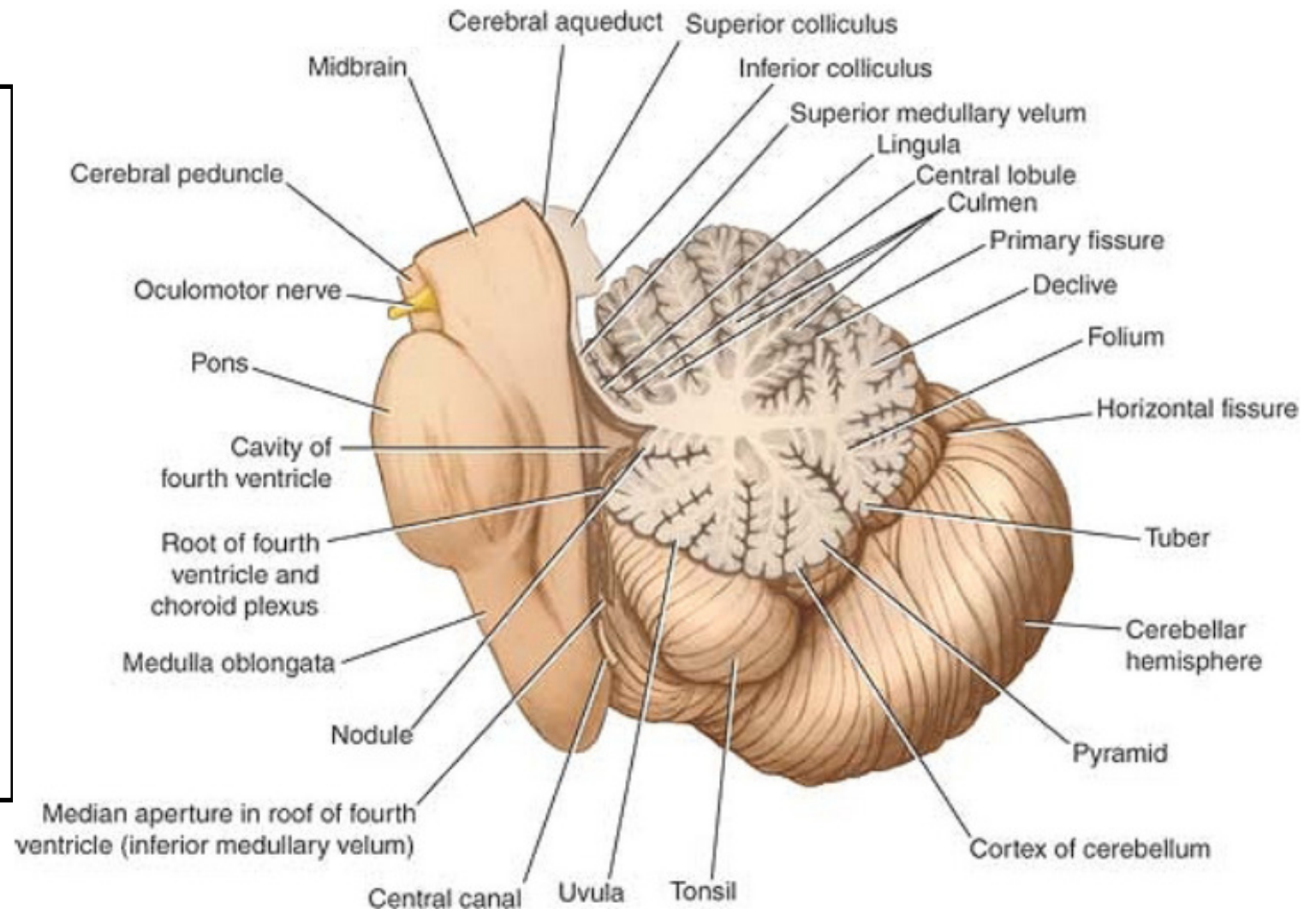
**Vermis** : influences the movements of the long axis of the body  
(neck, shoulders, thorax, abdomen and hips)

**Intermediate zone**: control muscles of the distal parts of the limbs  
(hand and feet)

**Lateral zone**: concerned with planning of sequential movements of the entire body



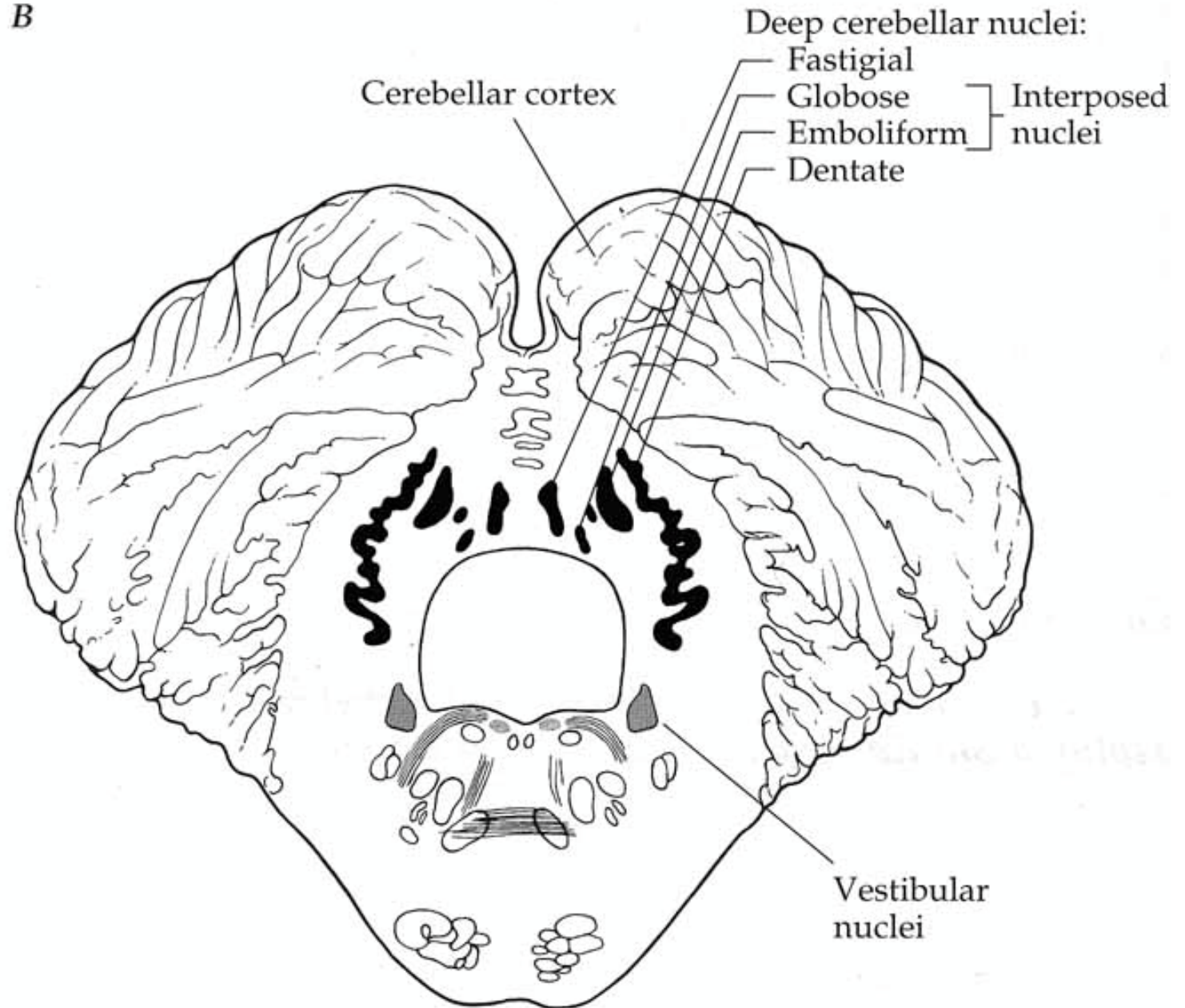
The cerebellum is composed of an outer covering of gray matter called the **cortex** and inner white matter Embedded in the white matter of each hemisphere three masses of gray matter forming the **intracerebellar nuclei**



Each ridge or gyrus in cerebellar cortex is called a **folium**, with a branched appearance called the **arbor vitae** (white matter)

# Deep cerebellar Nuclei

*B*



# Structure of cerebellar cortex

## 1- molecular layer

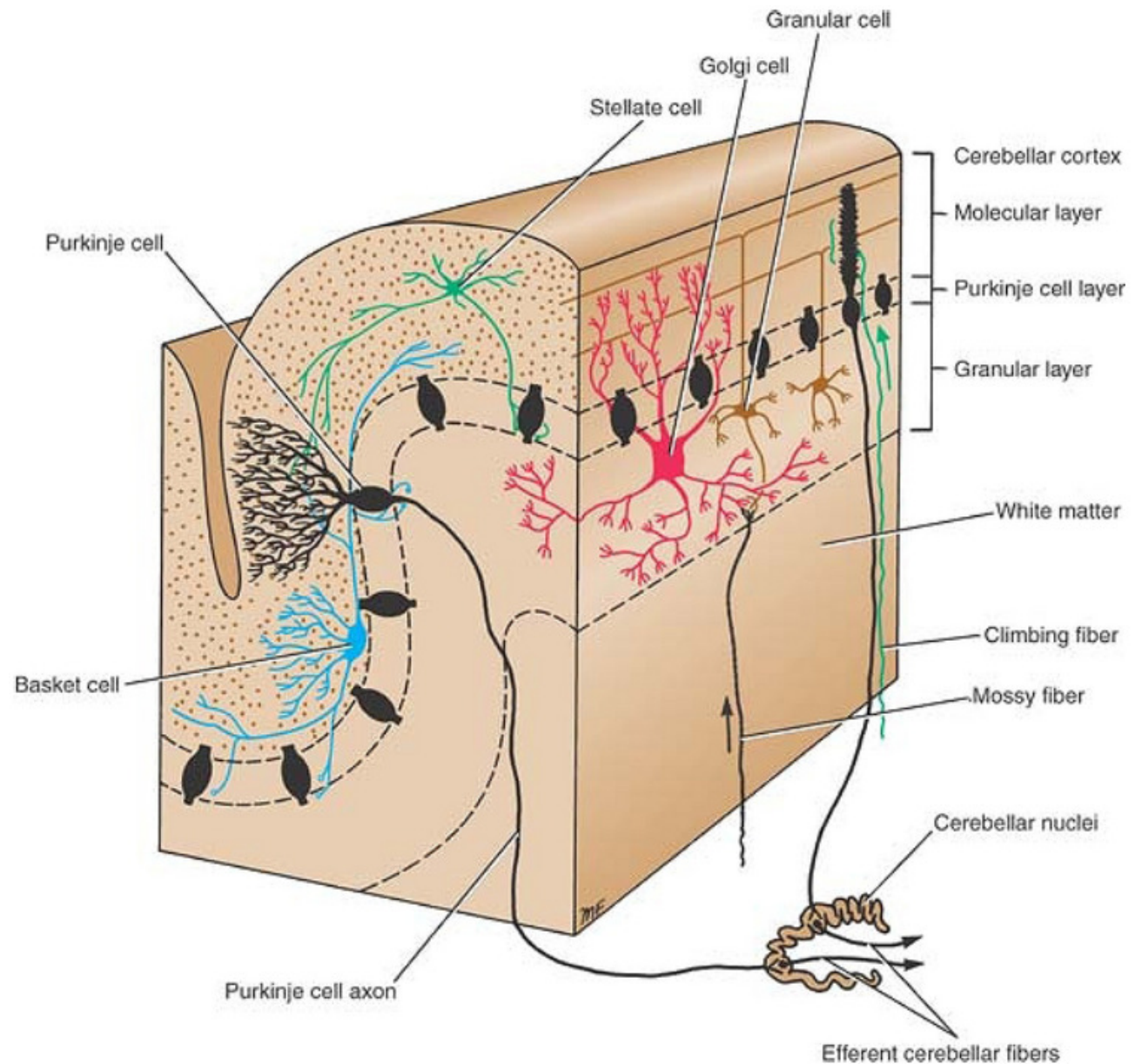
- stellate cell
- basket cell
- consisting of axons of granule cells (parallel fibers) and dendrites of Purkinje cells

## 2- Purkinje cell layer

- large neuronal cell bodies (Purkinje cells) Flask shaped cells

## 3- granular layer

- small neurons called granular cells
- Golgi cells: (Inhibitory)



# Cerebellar cortical mechanisms

**Input** to the cerebellar cortex:

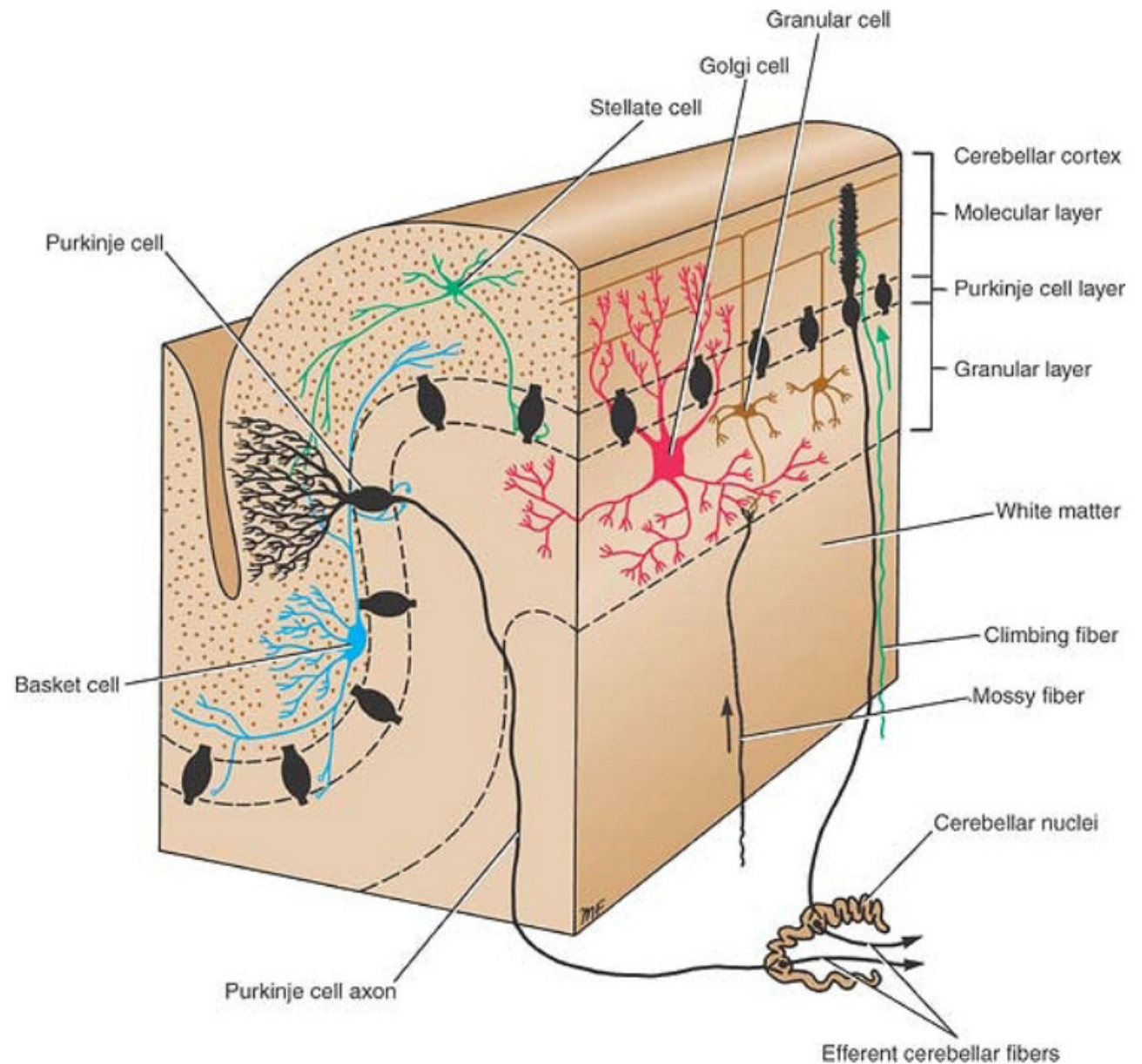
**1- Climbing fibers:**

terminal fibers of the olivocerebellar tracts

**2- Mossy fibers:**

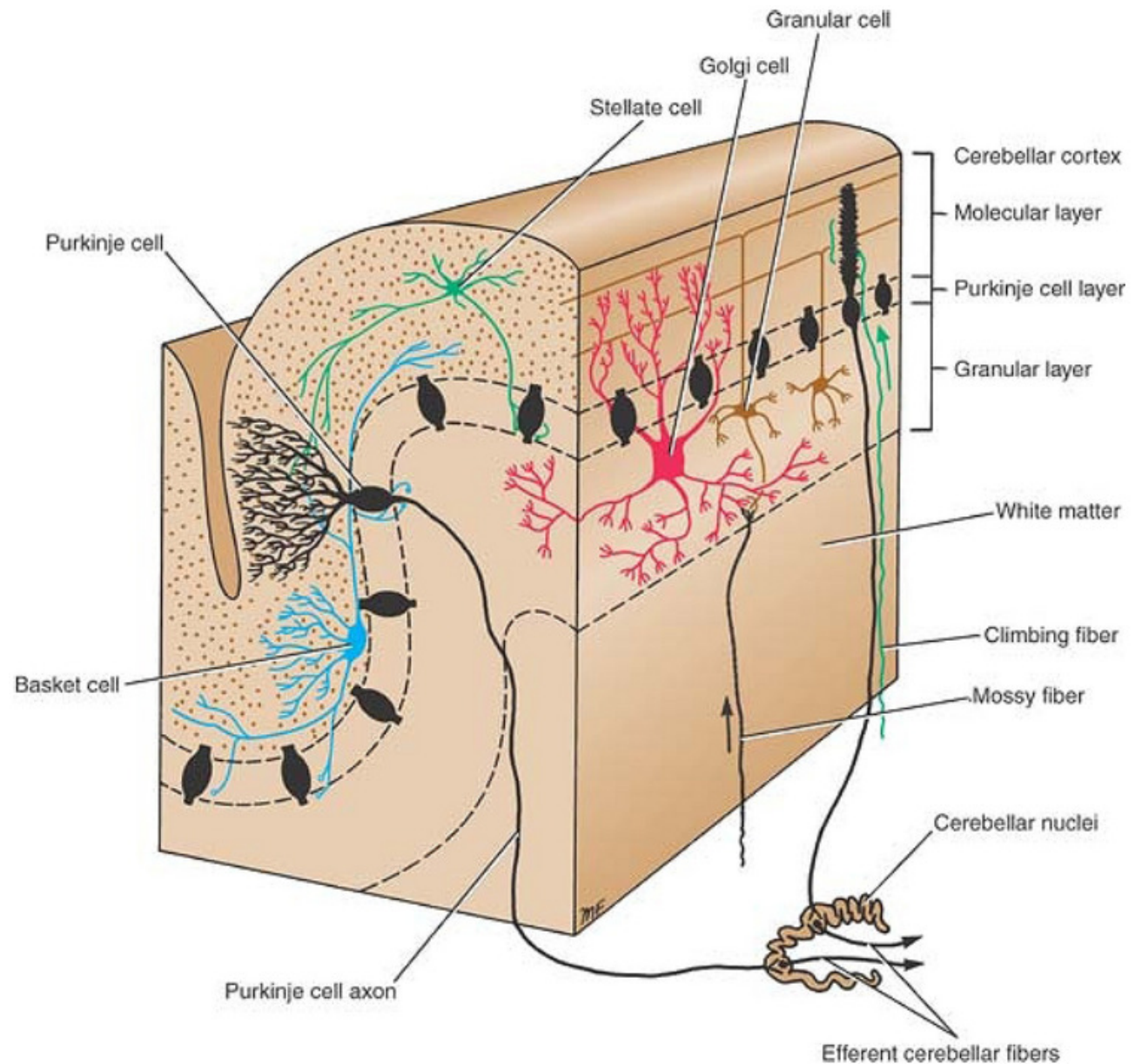
terminal fibers of all other cerebellar afferent tracts

Both are **excitatory** to purkinje cells



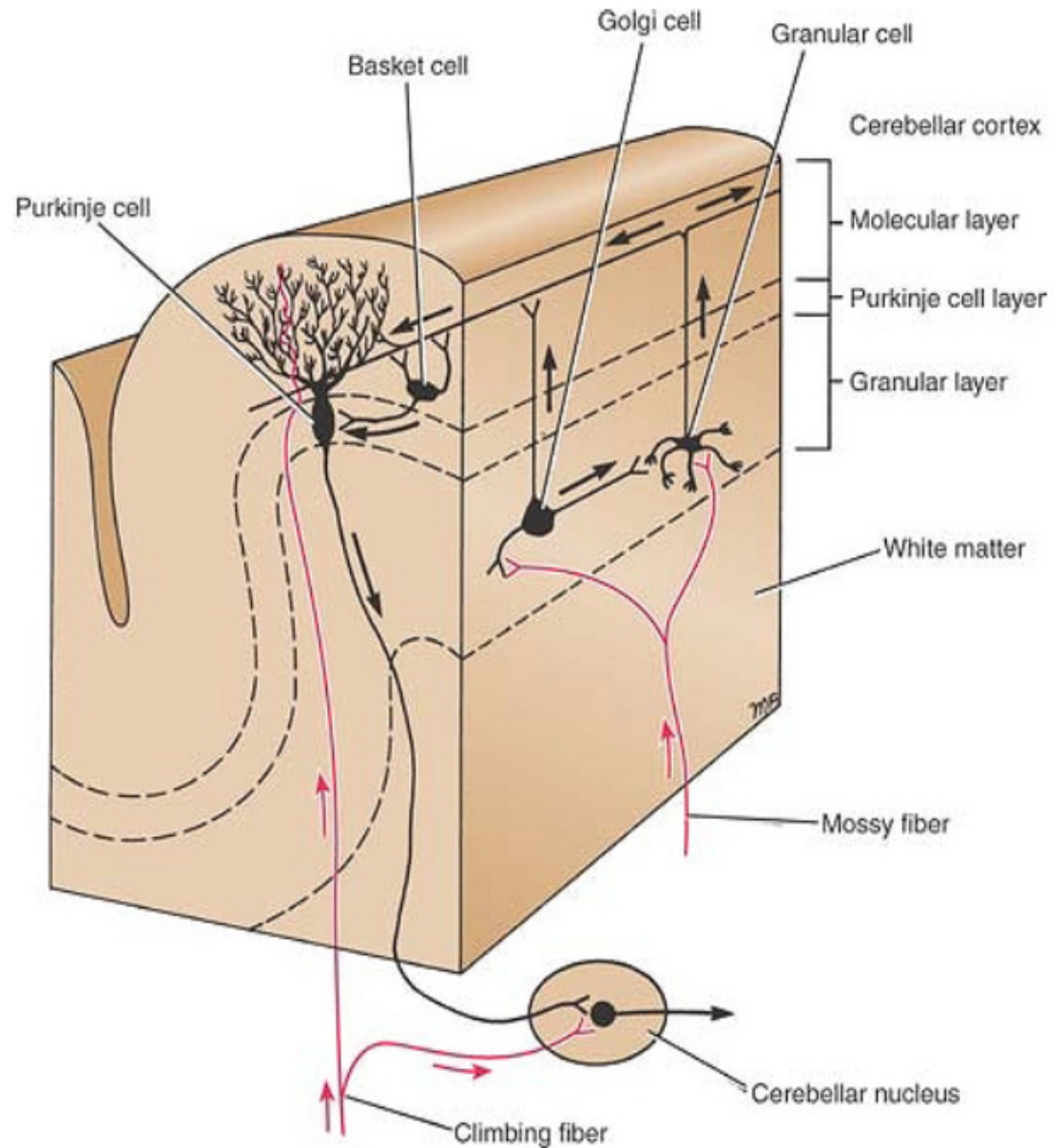
# Cerebellar cortical mechanisms

- a single purkinje neuron makes synaptic contact with only one climbing fiber
- one climbing fiber makes contact with one to ten purkinje neurons
- a single mossy fiber may stimulate thousands of purkinje cells through the granule cells
- Granule cells receive input from mossy fibers and project to the Purkinje cells



## Cerebellar cortical mechanisms

1. Purkinje Cells - the only output neuron from the cortex utilizes GABA to inhibit neurons in deep cerebellar nuclei
2. Granule Cells- intrinsic cells of cerebellar cortex; use glutamate as an excitatory transmitter; excites Purkinje cells via axonal branches called “parallel fibers”
3. Basket Cells and stellate cells- inhibitory interneuron; utilizes GABA to inhibit Purkinje cells

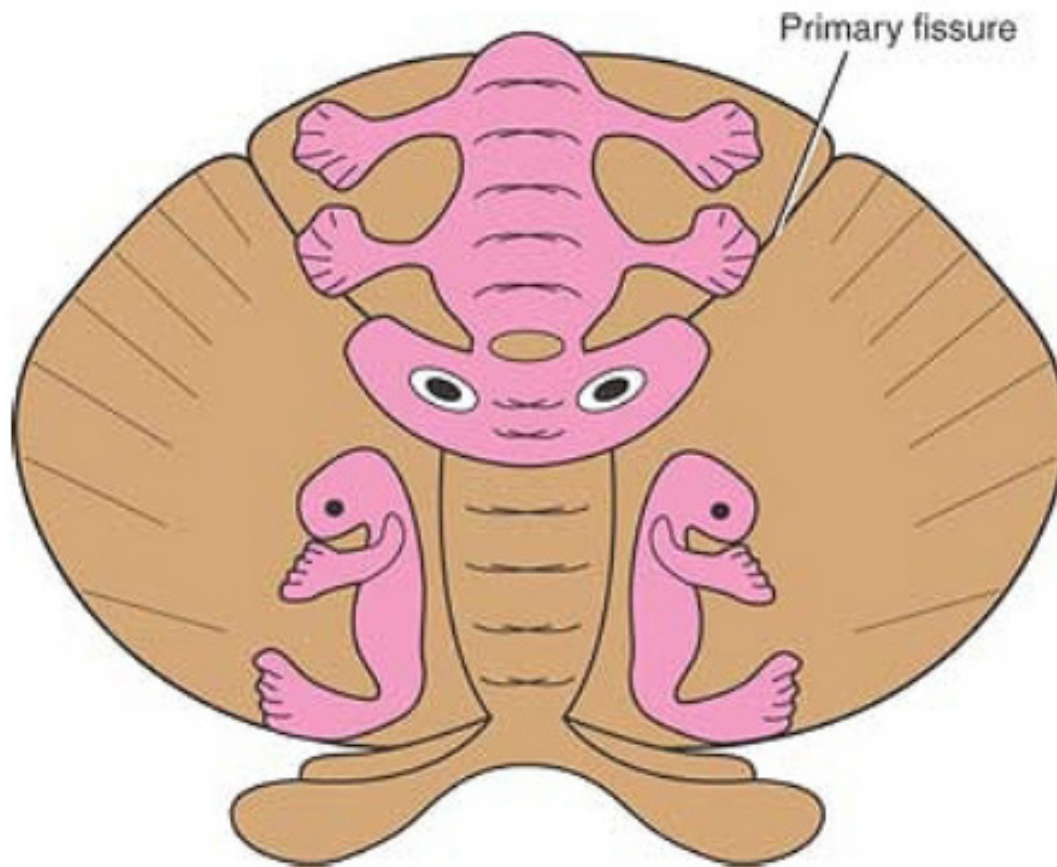


## Functional anatomy

A. Spinocerebellum

B. Cerebrocerebellum

C. Vestibulocerebellum



# Spinocerebellum

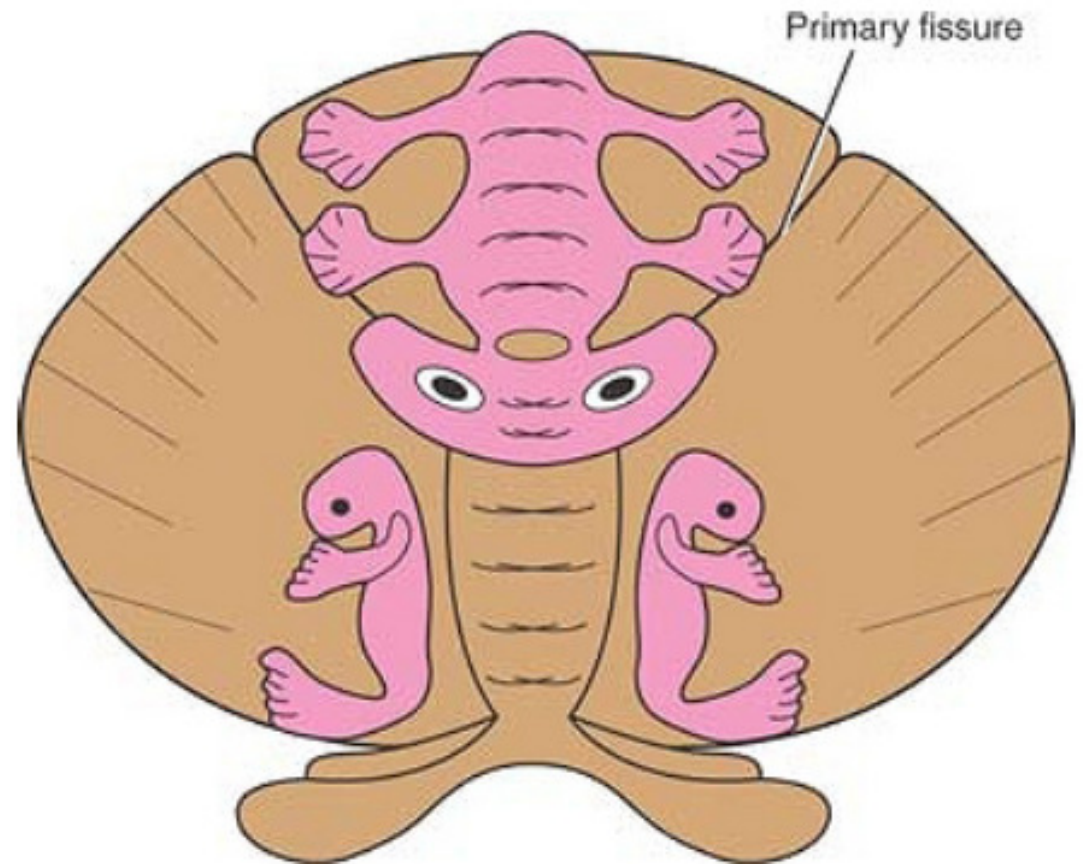
➤ most of the vermis of the posterior and anterior cerebellum plus the adjacent intermediate zones on both sides of the vermis.

# Cerebrocerebellum

➤ lateral zones of the cerebellar hemispheres, lateral to the intermediate zones

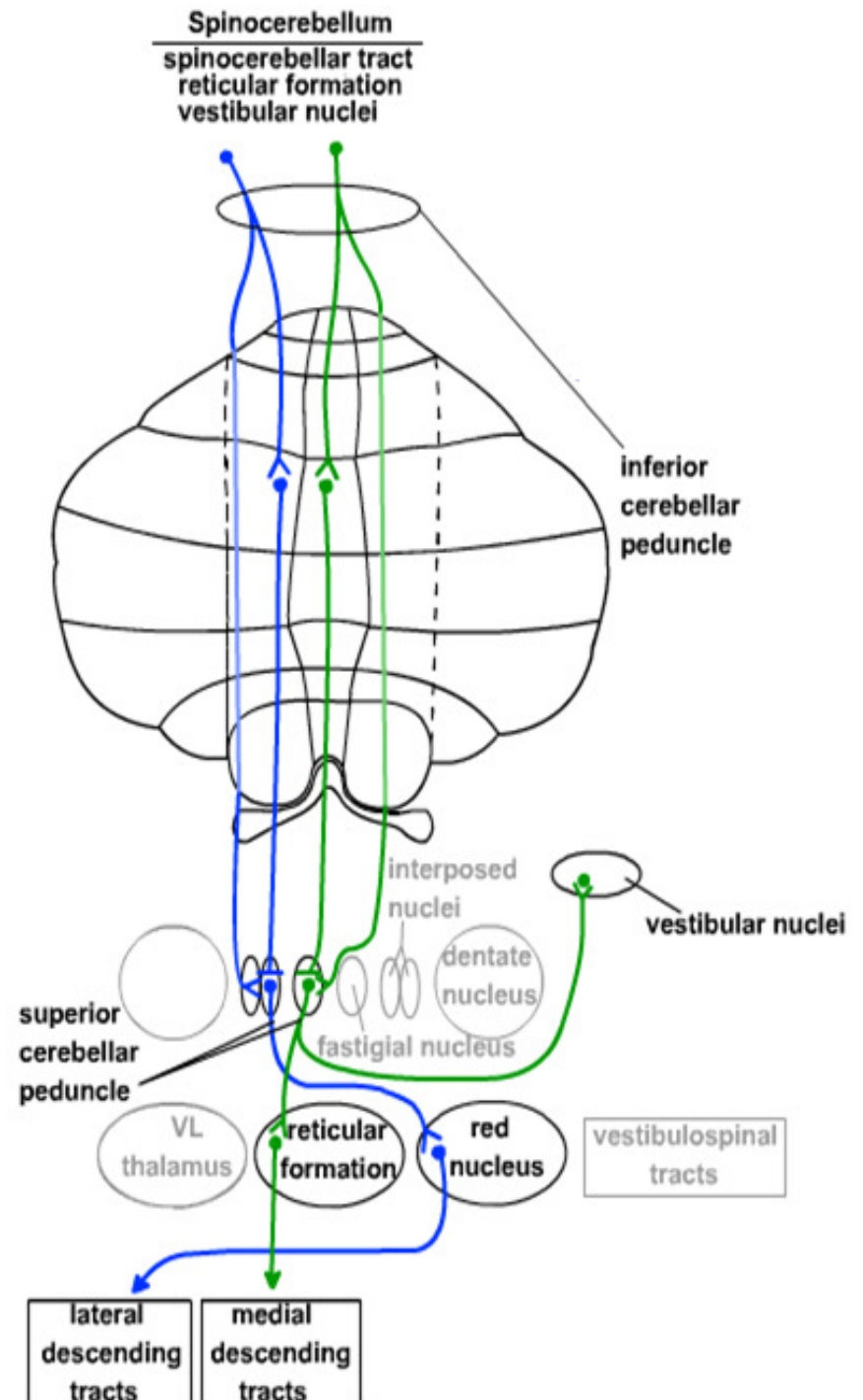
# Vestibulocerebellum

➤ small flocculonodular cerebellar lobes and adjacent portions of the vermis



# Spinocerebellum

- comprises the vermis + intermediate hemisphere of the cerebellar cortex, as well as the **fastigial** and **interposed nuclei**.
- projects through fastigial and interposed nuclei.
- has a somatotropic organization.
- it receives major inputs from the spinocerebellar tracts.
- Its output projects to rubrospinal, vestibulospinal, and reticulospinal tracts
- It is involved in the integration of sensory input with motor commands to produce adaptive motor coordination
- controls posture and movement of trunk and limbs.



# Spinocerebellum

the **vermis** will send efferents through fastigial n.

Inferior cerebellar peduncles

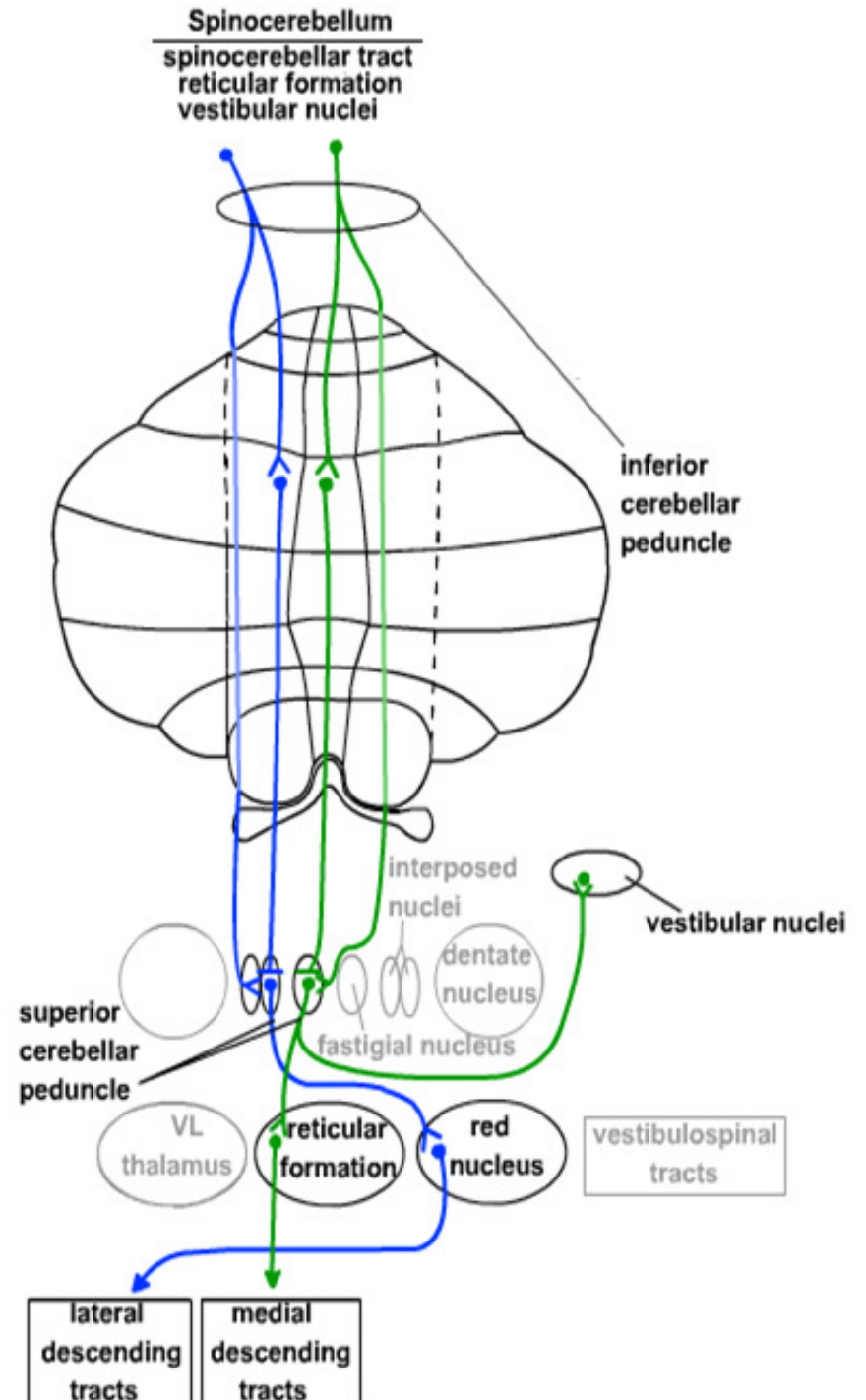
VL

Medial descending pathways:  
(Anterior column)  
**A**-fastigial vestibular pathway  
(*vestibulospinal tract*)

**B**-fastigial reticular pathway  
(*reticulospinal tract*)

1° motor ctx descends

Medial (anterior)  
Corticospinal tract



# Spinocerebellum

The **intermediate hemisphere** will send efferents through interposed n.

Superior cerebellar peduncle

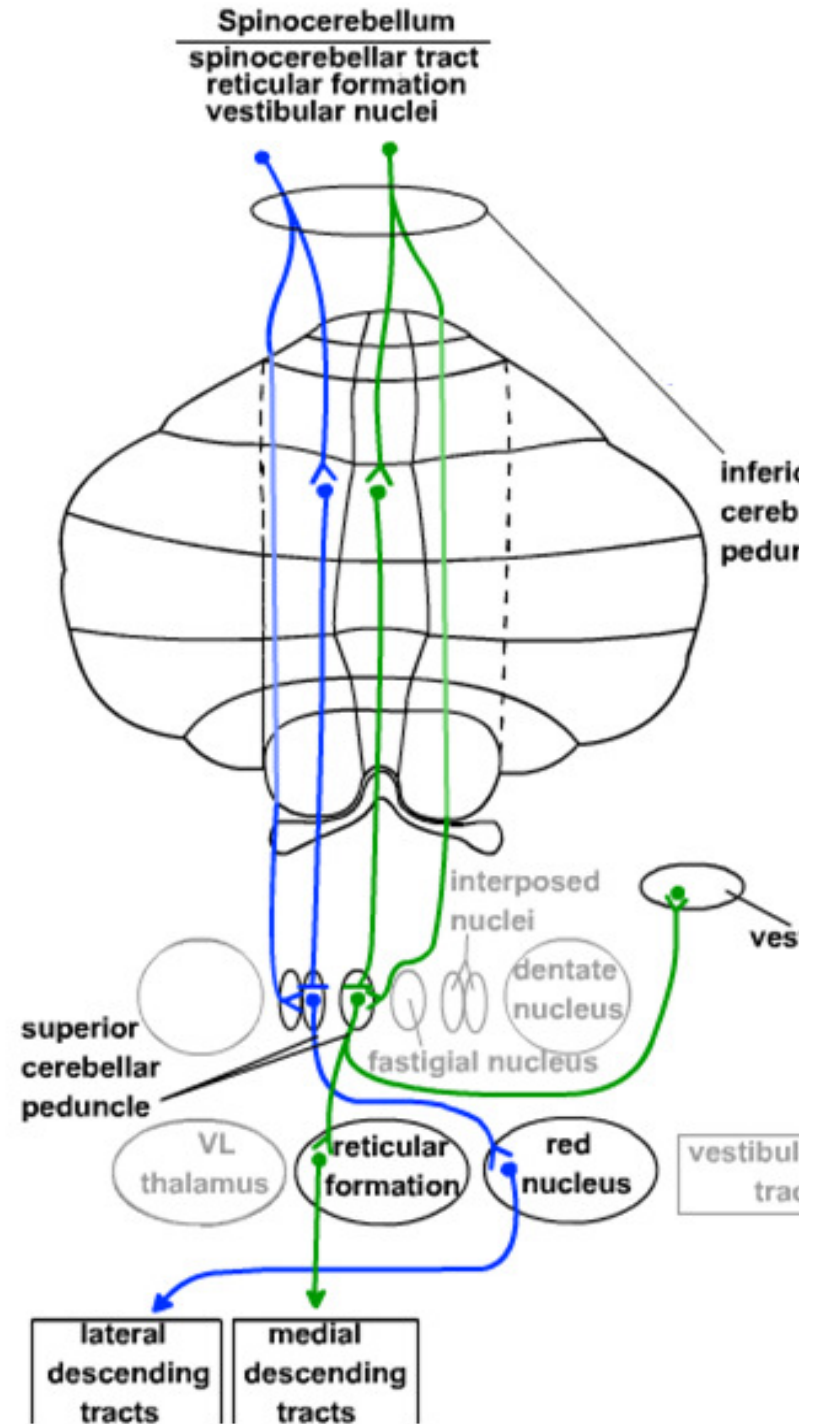
Red nucleus

VL

Globose-emboliform-rubral pathway  
(*Rubrospinal tract*)

1° motor ctx descends

Lateral cortico-spinal tract



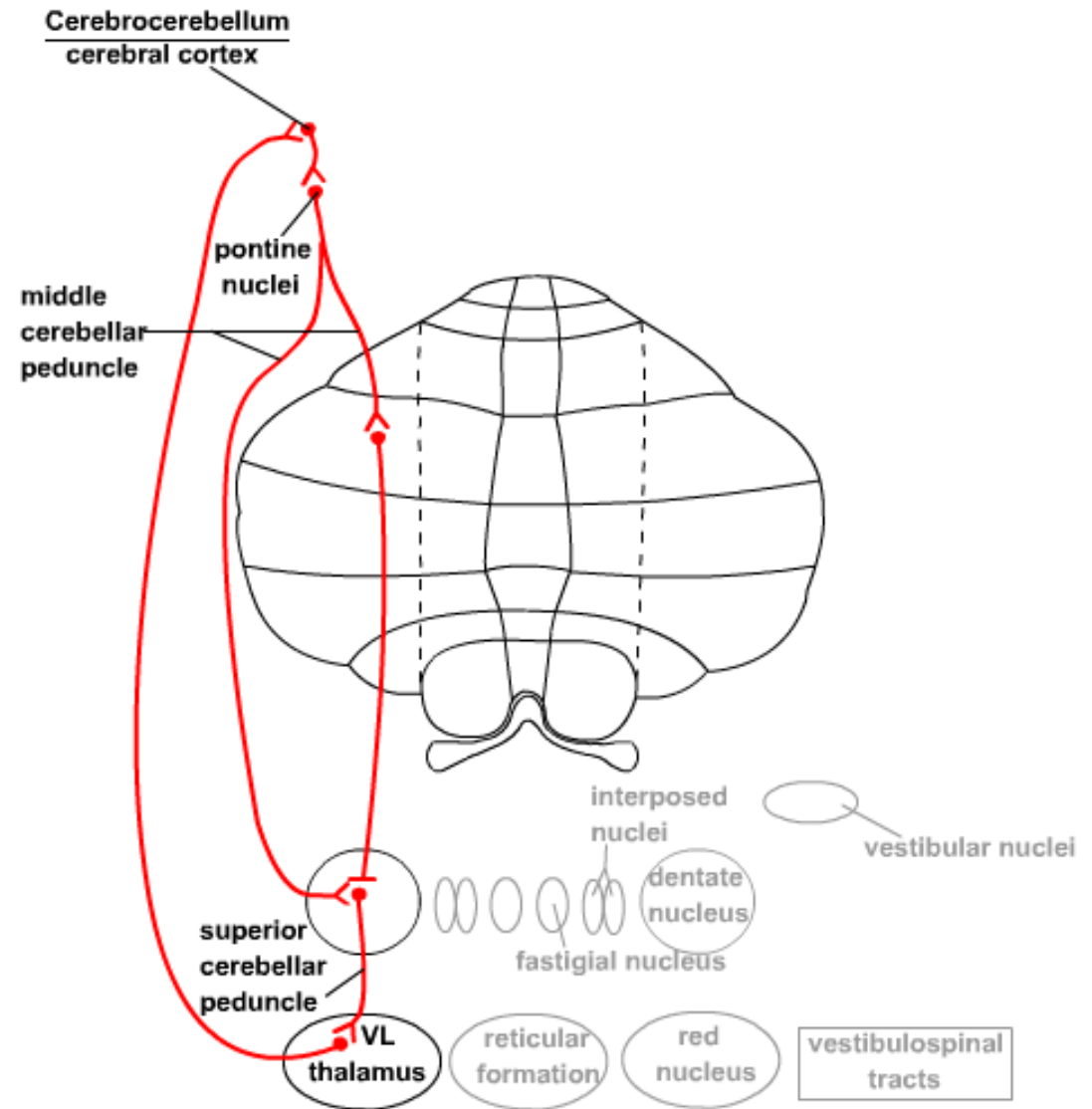
# Cerebrocerebellum

- participates in the planning of movement
- located in the lateral hemisphere
- projects to the dentate nucleus
- from its extensive connections with the cerebral cortex, via the pontine nuclei (afferents) and the VL thalamus (efferents). It is involved in the planning and timing of movements.

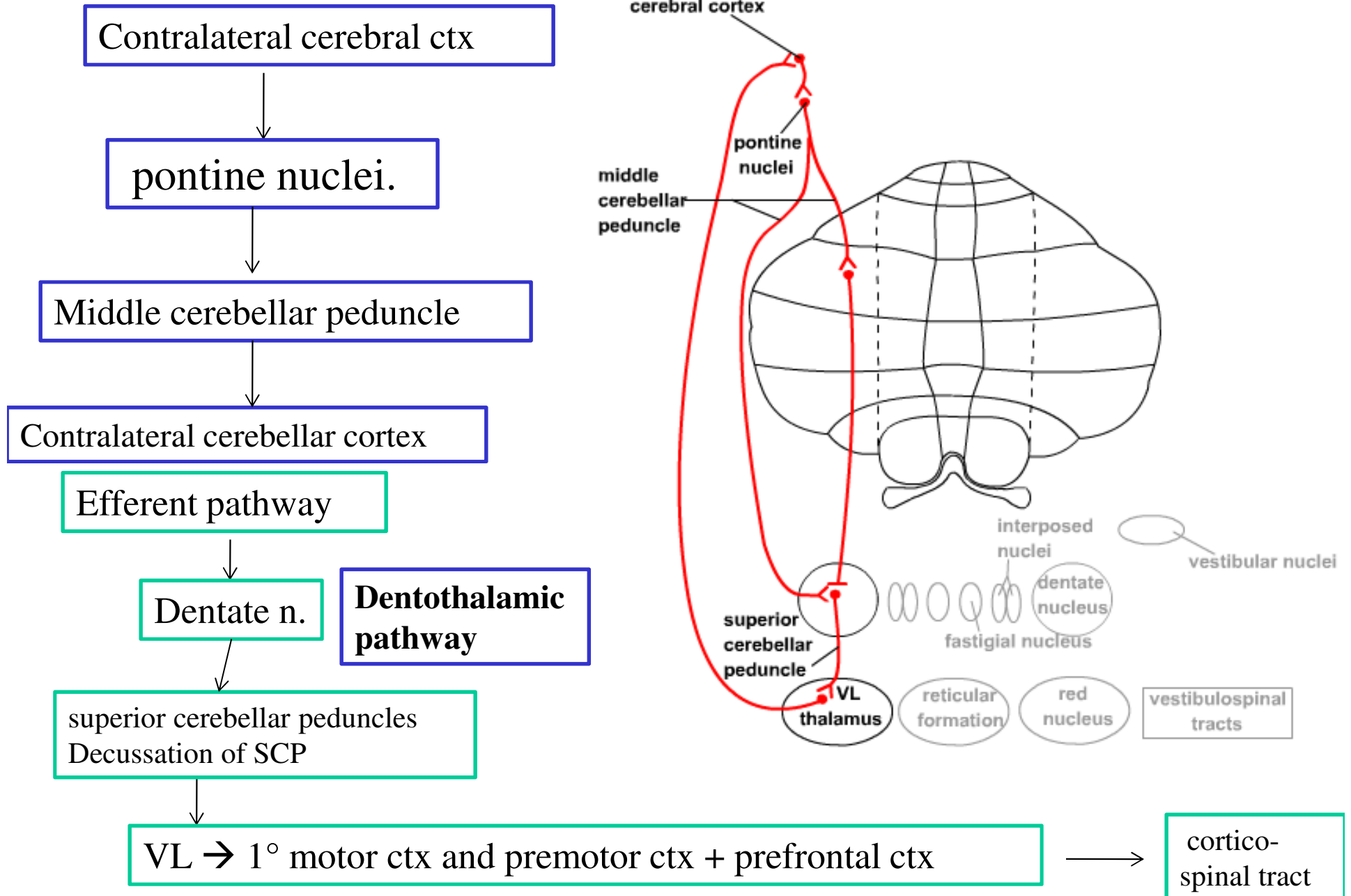
-- **Afferent input** : from entire contralateral cerebral cortex

-- **Efferent pathway** : thalamus

comprising the **lateral hemispheres** and the **dentate nuclei**



# Cerebrocerebellum



# Vestibulocerebellum

- functions in maintaining balance and controlling head and eye movements.
- located in flocculonodular lobe.
- projects to vestibular nuclei.
- it is involved in vestibular reflexes (such as the vestibuloocular reflex) and in postural maintenance.

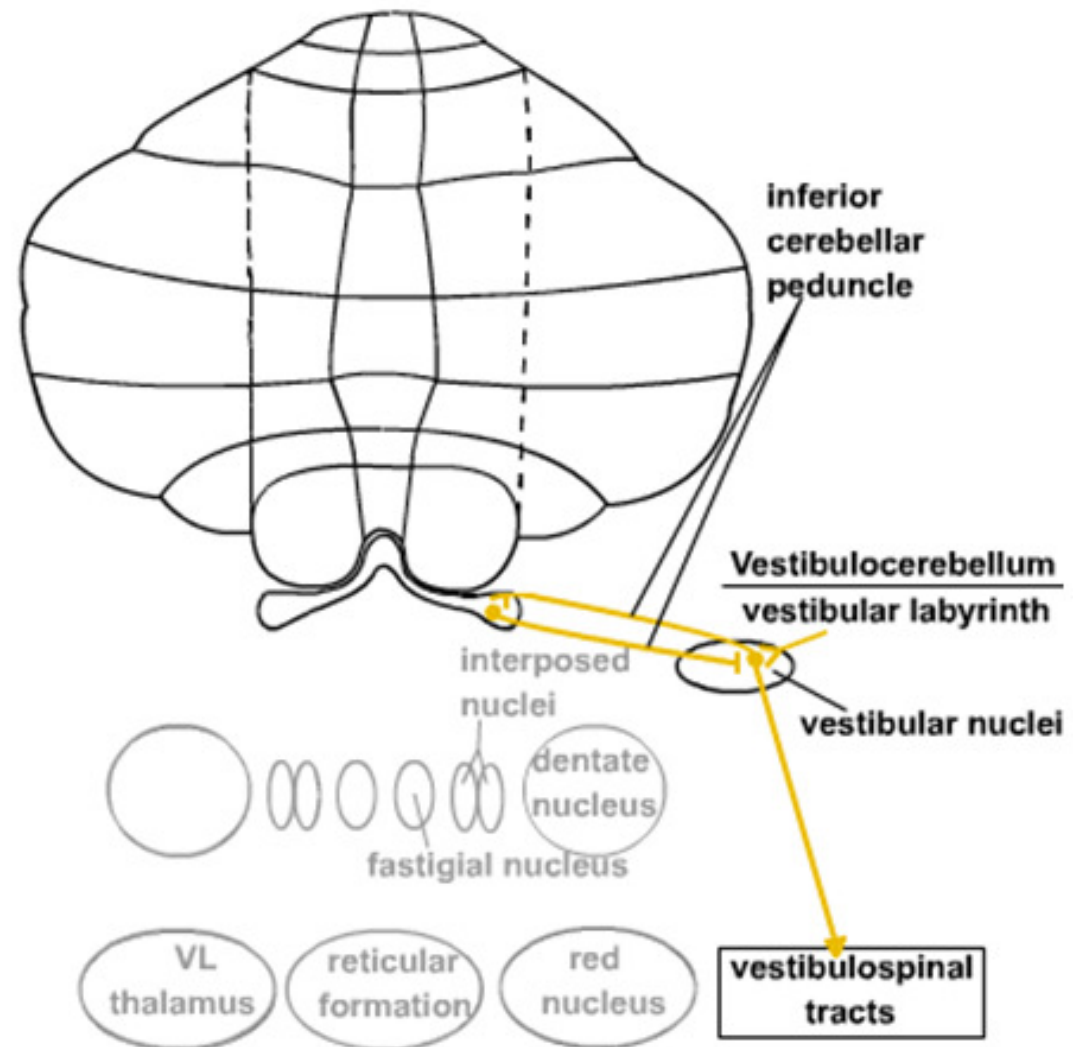
## Afferent input:

vestibular nerve and vestibular nuclei.

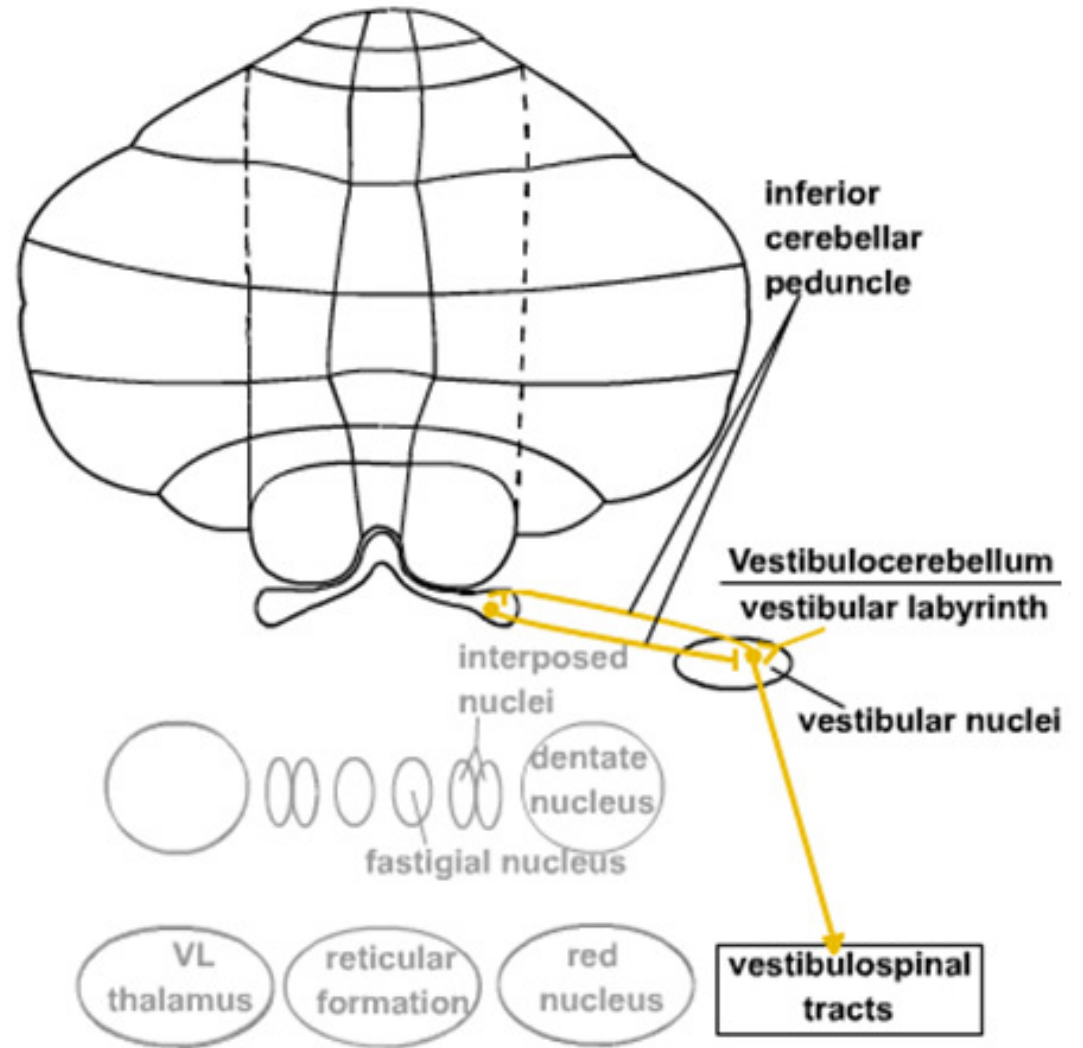
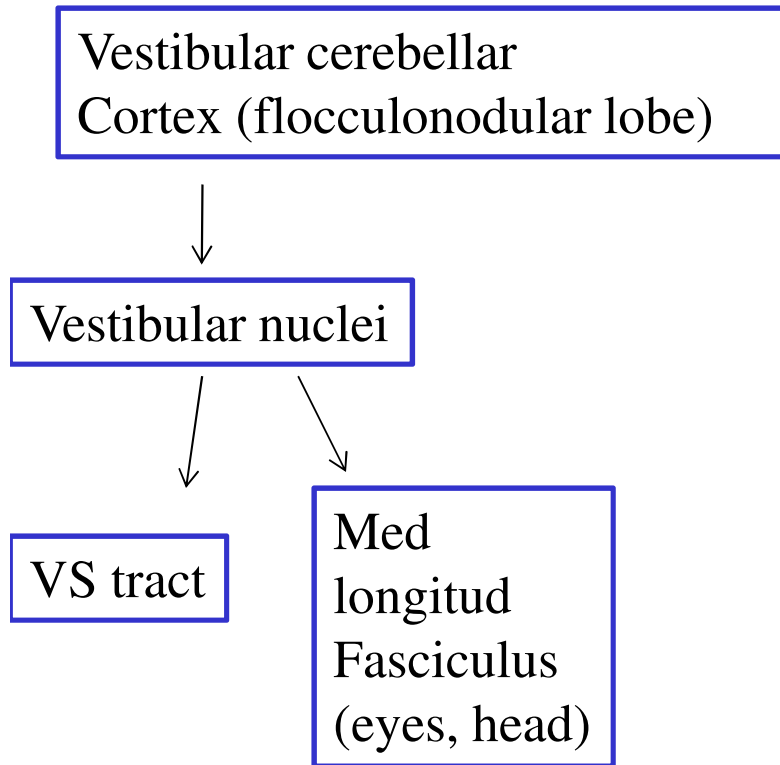
## Efferent path

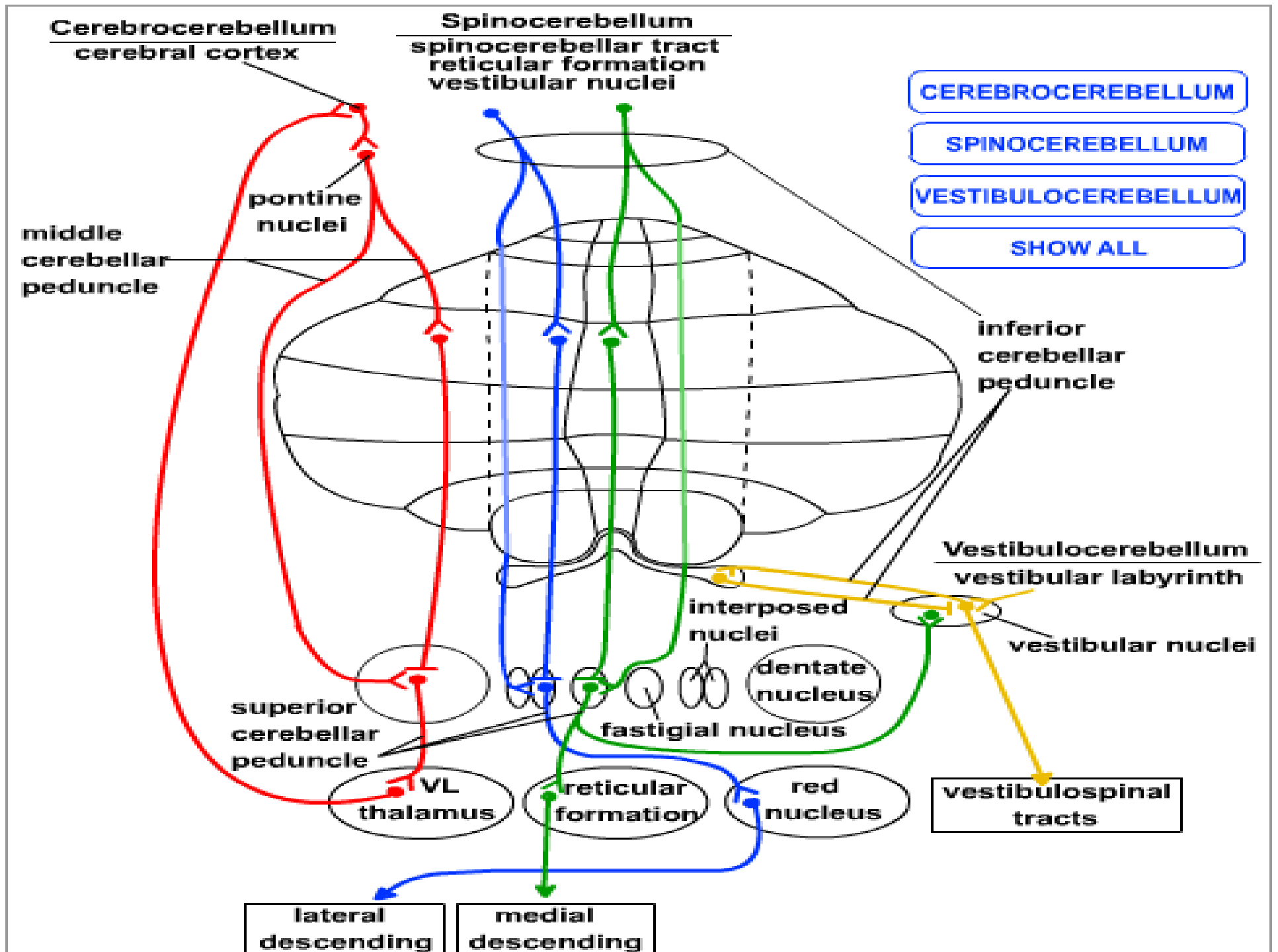
**vestibular nuclei**

comprises the **flocculonodular lobe** and its connections with the **lateral vestibular nuclei**



# Vestibulocerebellum





# Cerebellar afferent fibers

## ➤ From cerebral cortex

1. Corticopontocerebellar pathway
2. Cerebro-olivocerebellar pathway
3. Cerebroreticulocerebellar pathway

## ➤ From vestibular nerve

## ➤ From spinal cord

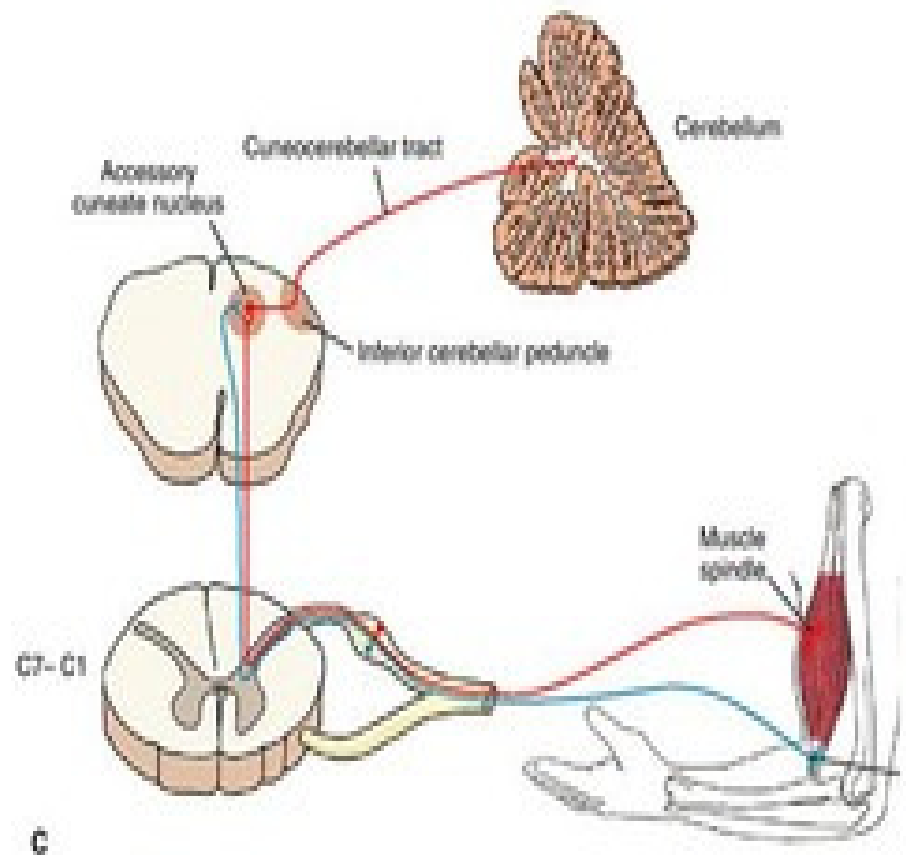
1. Anterior spinocerebellar tract
2. Posterior spinocerebellar tract
3. Cuneocerebellar tract

## ➤ Other afferents

1. Red nucleus
2. Tectum

# Cuneocerebellar tract

- Originate in nucleus cuneatus of medulla oblongata
- Enter the ICP (ipsilateral)
- Receives proprioception (muscle-joint sensations) from the upper limb and upper part of thorax



# Cerebellar efferent fibers

- Dentothalamic pathway
- Globose-emboliform-rubral pathway
- Fastigial vestibular pathway
- Fastigial reticular pathway

The **inferior cerebellar peduncle**: primarily contains **afferent** fibers from the medulla, as well as **efferents** to the vestibular nuclei.

The **middle cerebellar peduncle**: primarily contains **afferents** from the pontine nuclei.

The **superior cerebellar peduncle**: primarily contains **efferent** fibers from the cerebellar nuclei, as well as some afferents from the spinocerebellar tract.

## Signs and symptoms of cerebellar disease

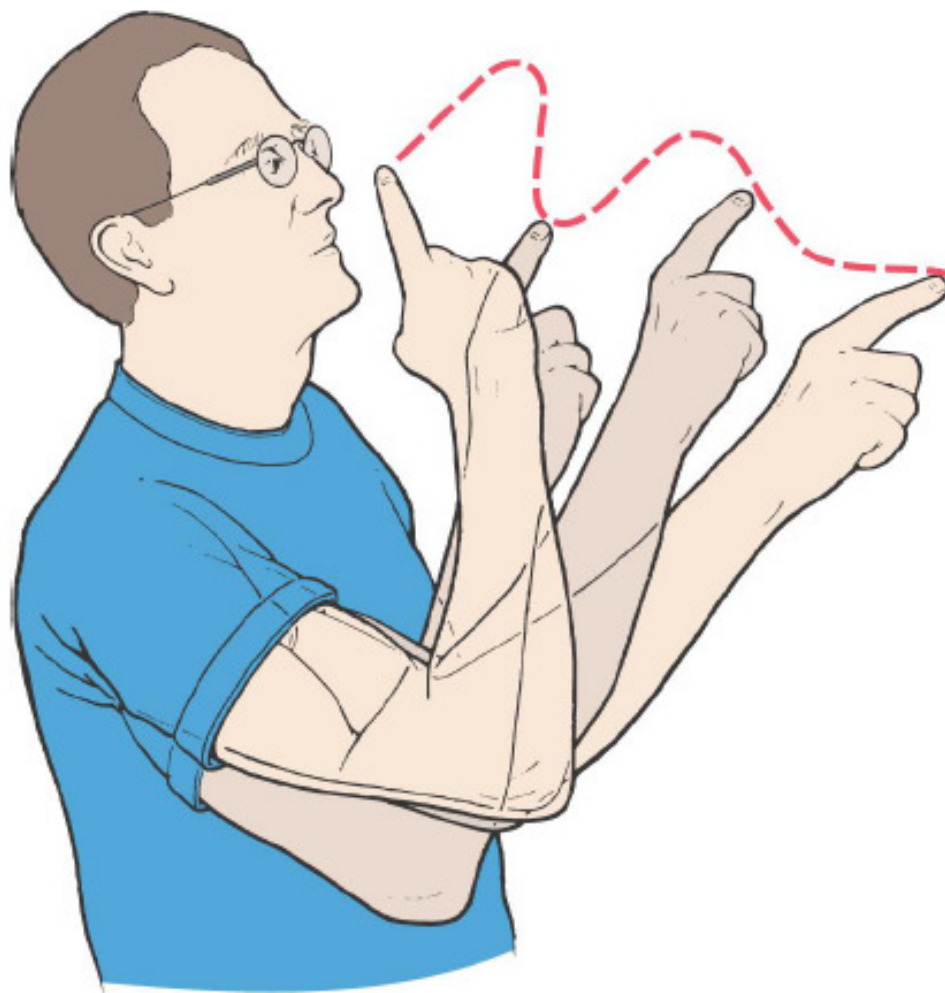➤ A lesion in one cerebellar hemisphere gives rise to signs and symptoms that are limited to the *same side* of the body

➤ **Hypotonia**: decrease in muscle tone:  
(Loss of the deep cerebellar nuclei, particularly of the interposed nuclei)

➤ **Dysmetria** (past pointing):  
movements ordinarily overshoot their intended mark; then the conscious portion of the brain overcompensates in the opposite direction for the succeeding compensatory movement.

➤ **Ataxia** (inaccuracy and disturbances of voluntary movement)

➤ **Tremors**: involuntary oscillations of limbs (“intention tremor”), results from cerebellar overshooting and failure of the cerebellar system to “damp” the motor movements



# Signs and symptoms of cerebellar disease

**Postural changes** and alteration of gait (wide-based gait) to compensate for loss of muscle tone

➤ **Failure of Progression**

▪ **Dysdiadochokinesia** (difficulty performing rapid alternating movements) due to failure to predict where the different parts of the body will be at a given time during rapid motor movements.

▪ **Dysarthria:** Disorders of speech

**Nystagmus:** rhythmic oscillations of the eyes. It occurs especially when the flocculonodular lobes of the cerebellum are damaged;

